

The images in this file are the sole property of Dr. Regina Isabel Santos-Morales. These images should not be copied, shared, or used without the written consent of the owner.

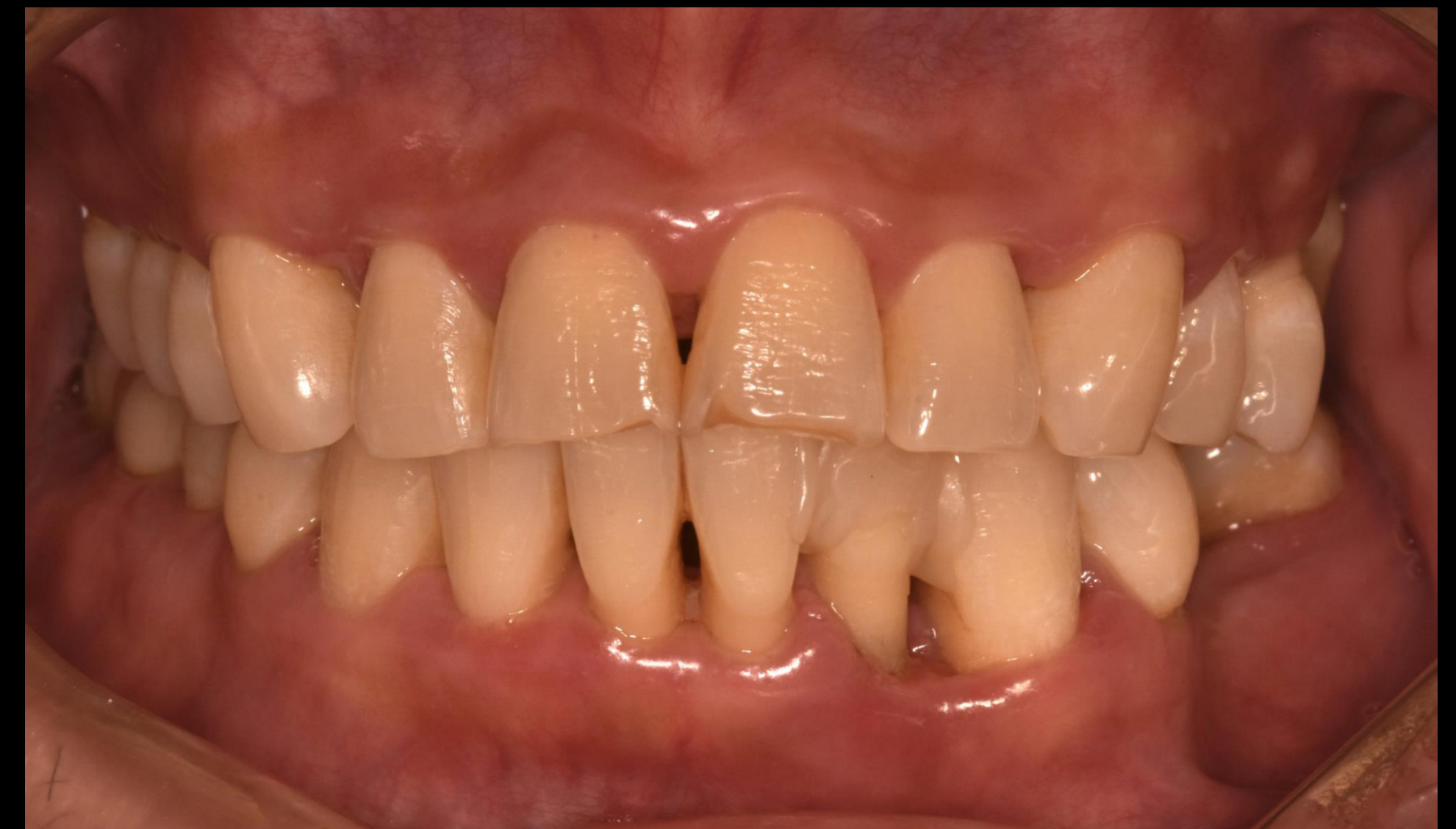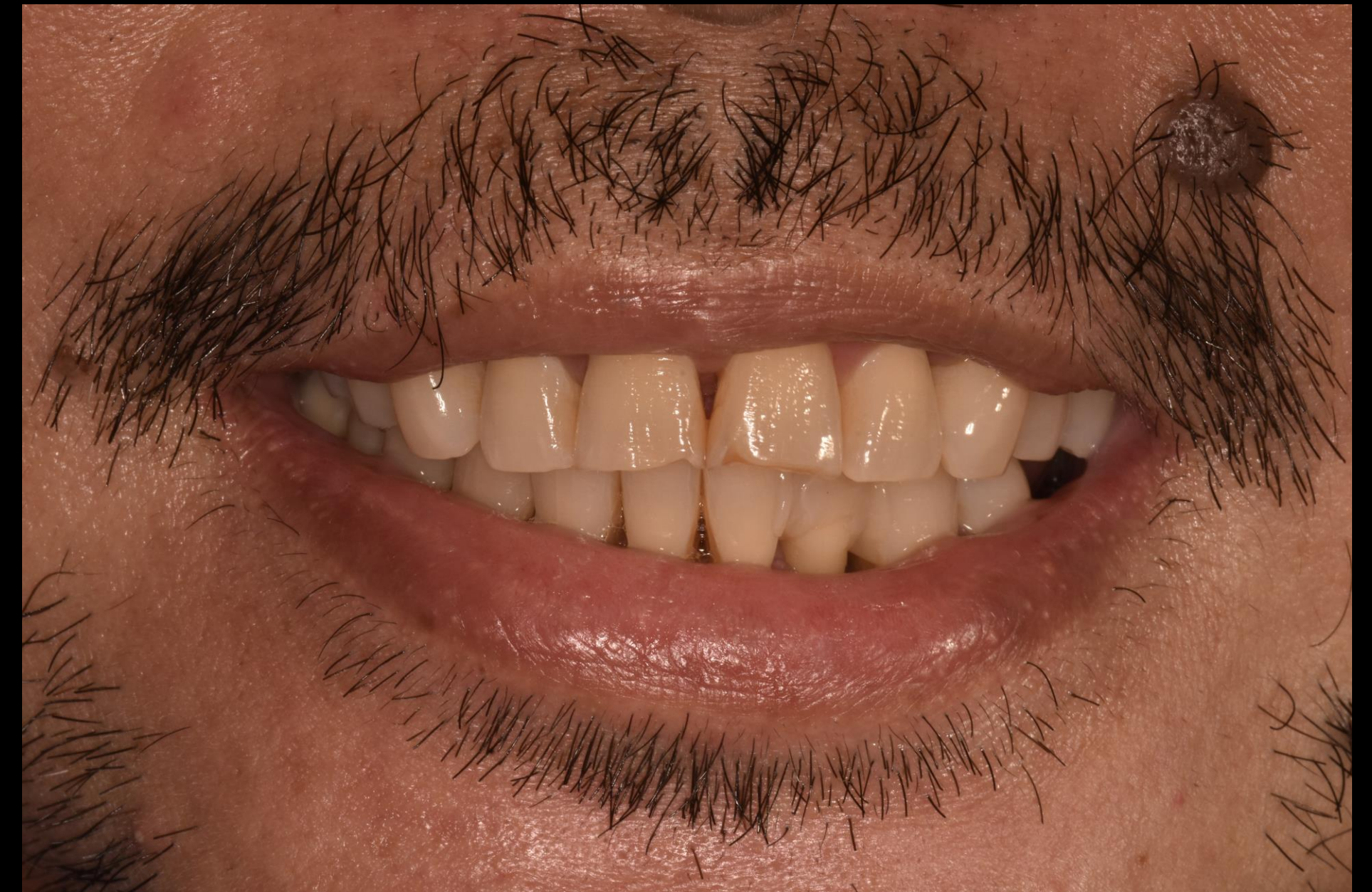Case #
Pt ID Code/Initial
Age/Gender
Name of Candidate

CHIEF COMPLAINT:

“My lower front teeth are moving and I was told I have severe gum problem.”

PAST DENTAL HISTORY

- Haven't seen a dentist since pandemic
- (+) bleeding gums, 20 years ago - he ignored it
- (+) swelling, he ignored it
- (+) mobility - lower front teeth
- (+) sensitivity to hot and cold - only after his last cleaning
- (+) sensitivity to sweets (a little)
- (+) bad taste/bad smell
- LL tooth removed by itself/ 2021
- 2 other teeth got pulled out



MEDICAL HISTORY

(+) Diabetes
currently doctor is measuring
his blood sugar level, one
week apart to know if he will
need medications

(-) smoking

(he has been puyat since he was told
he has severe gum problems)

MEDICATIONS:

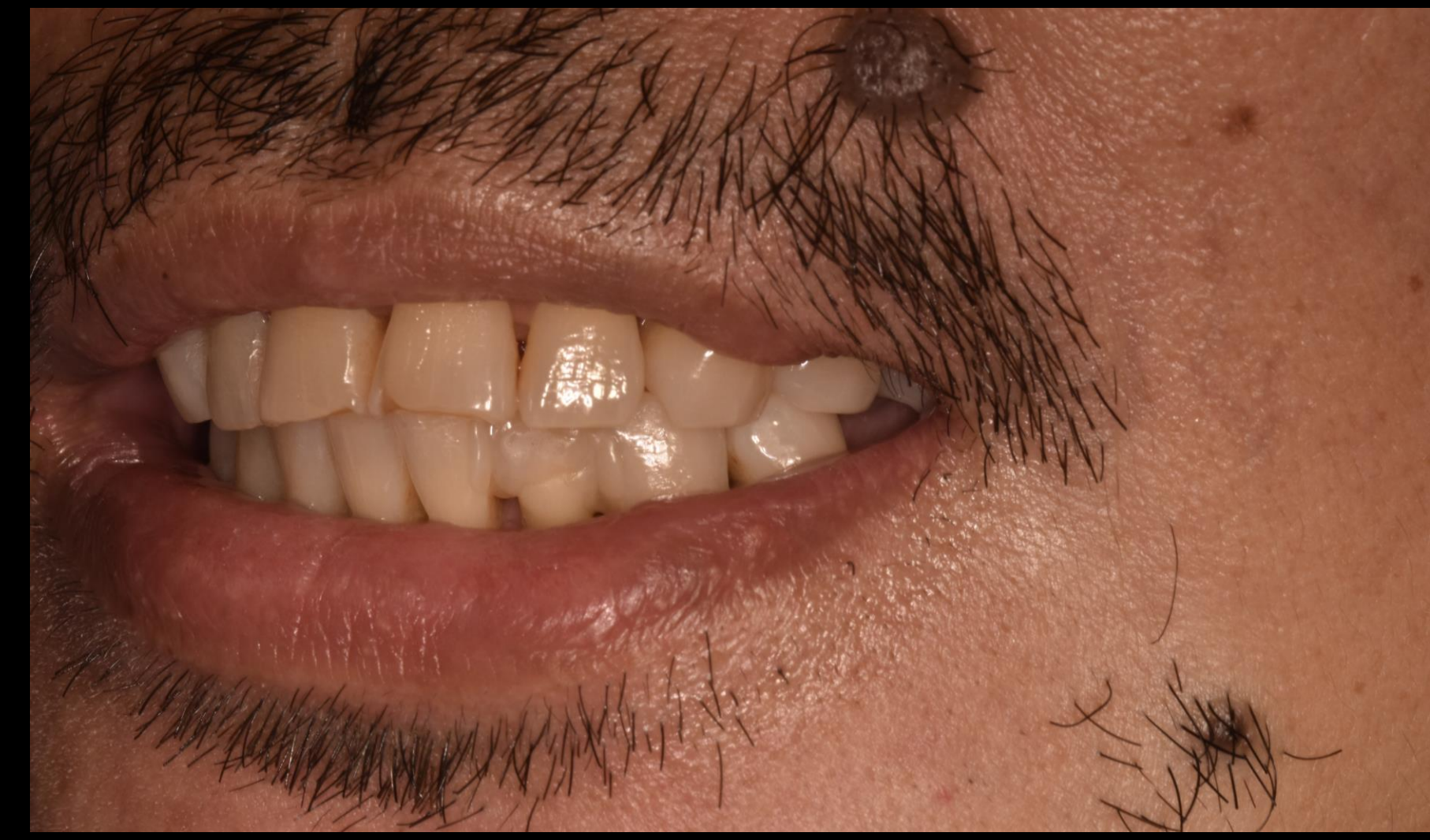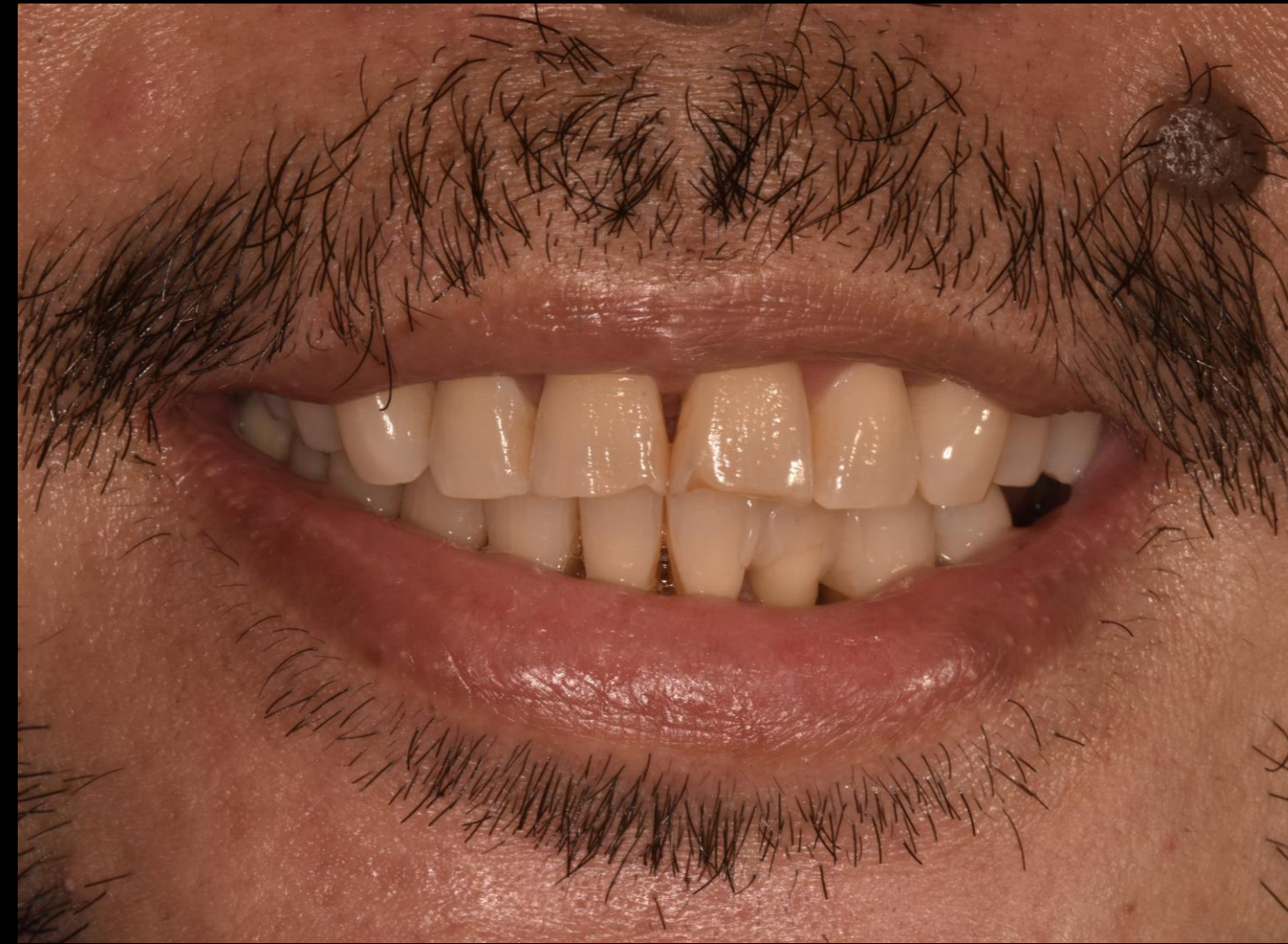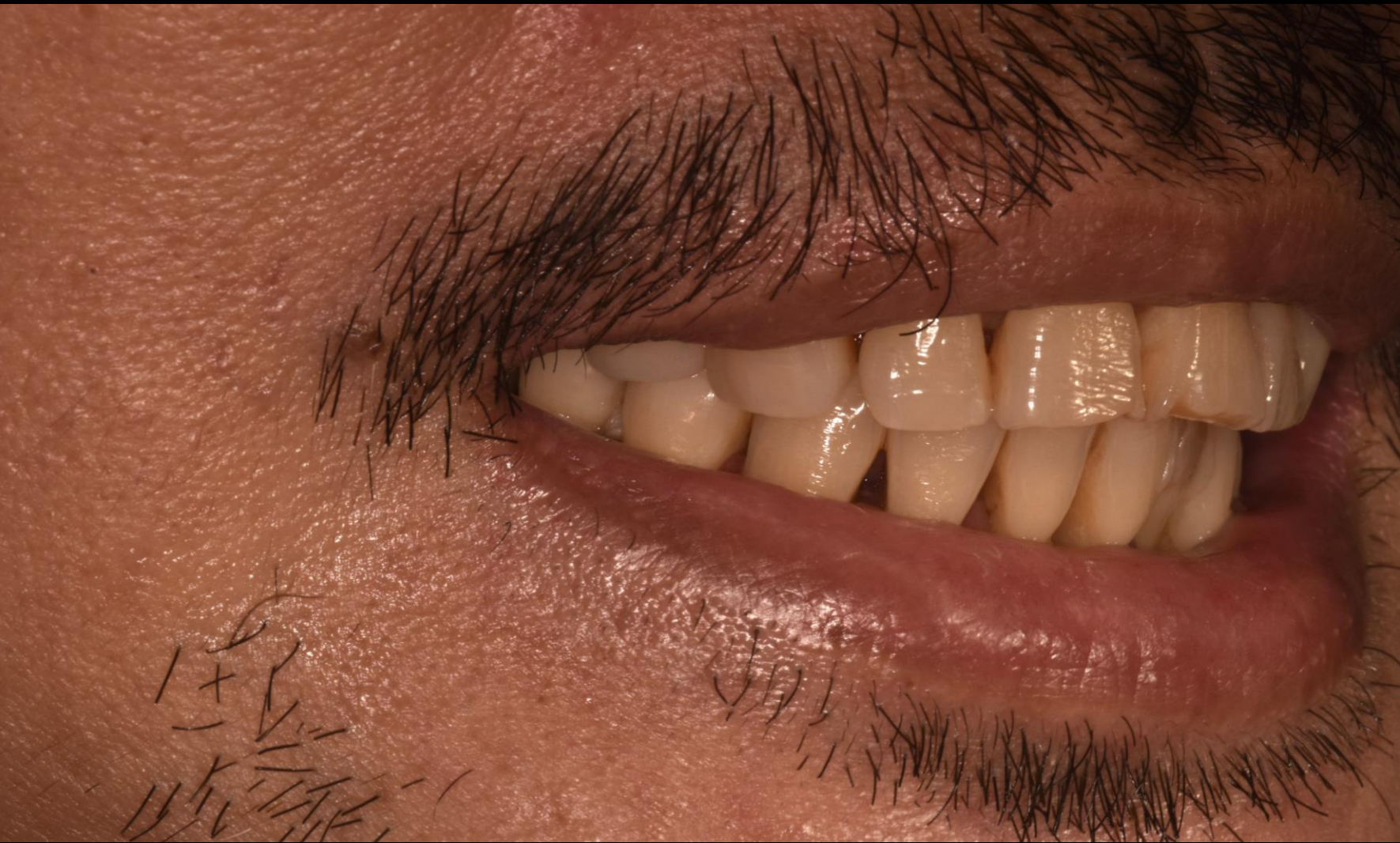
NO MEDICATIONS
vitamins: immunopro



EXTRA-ORAL FINDINGS:
INTRA-ORAL FINDINGS:

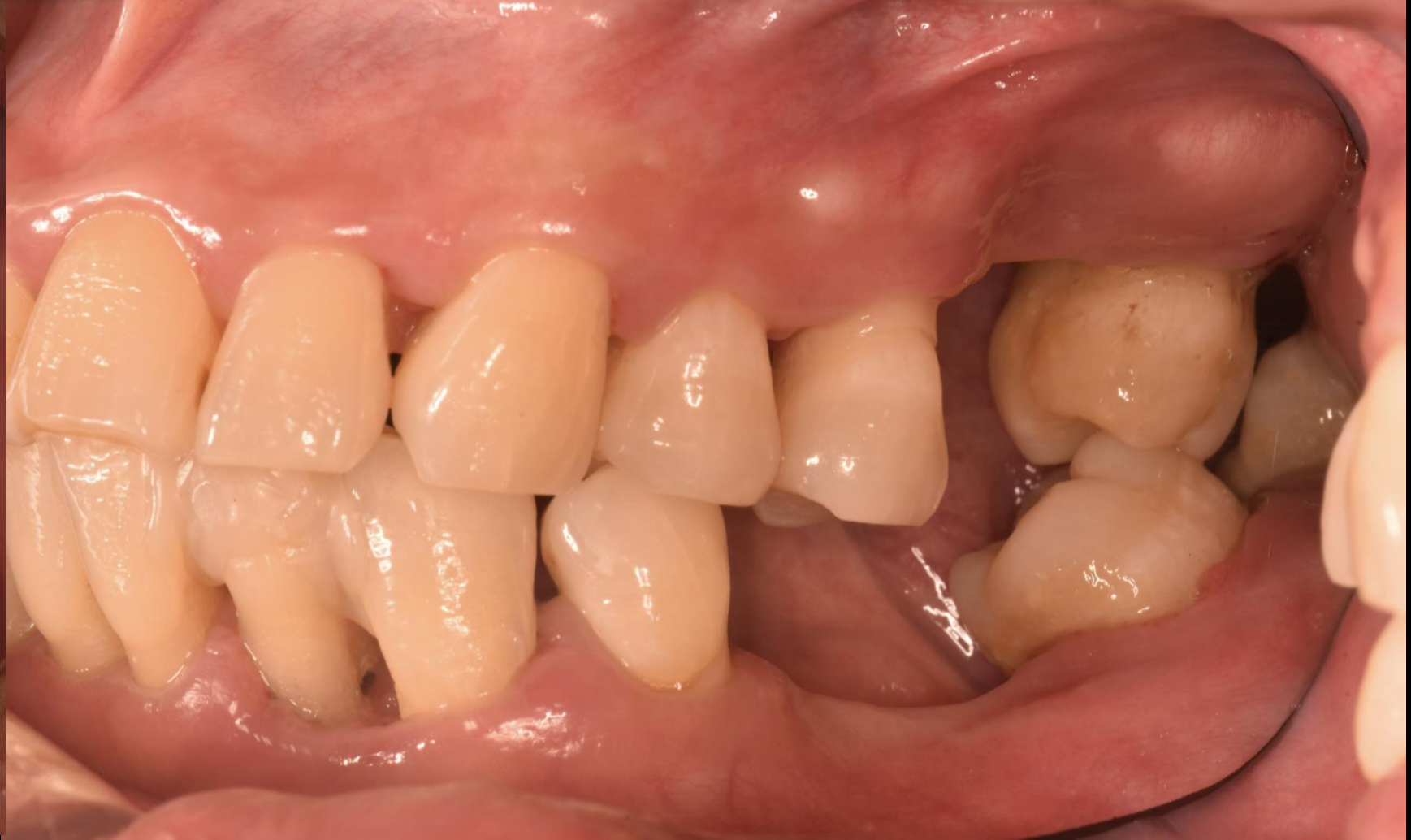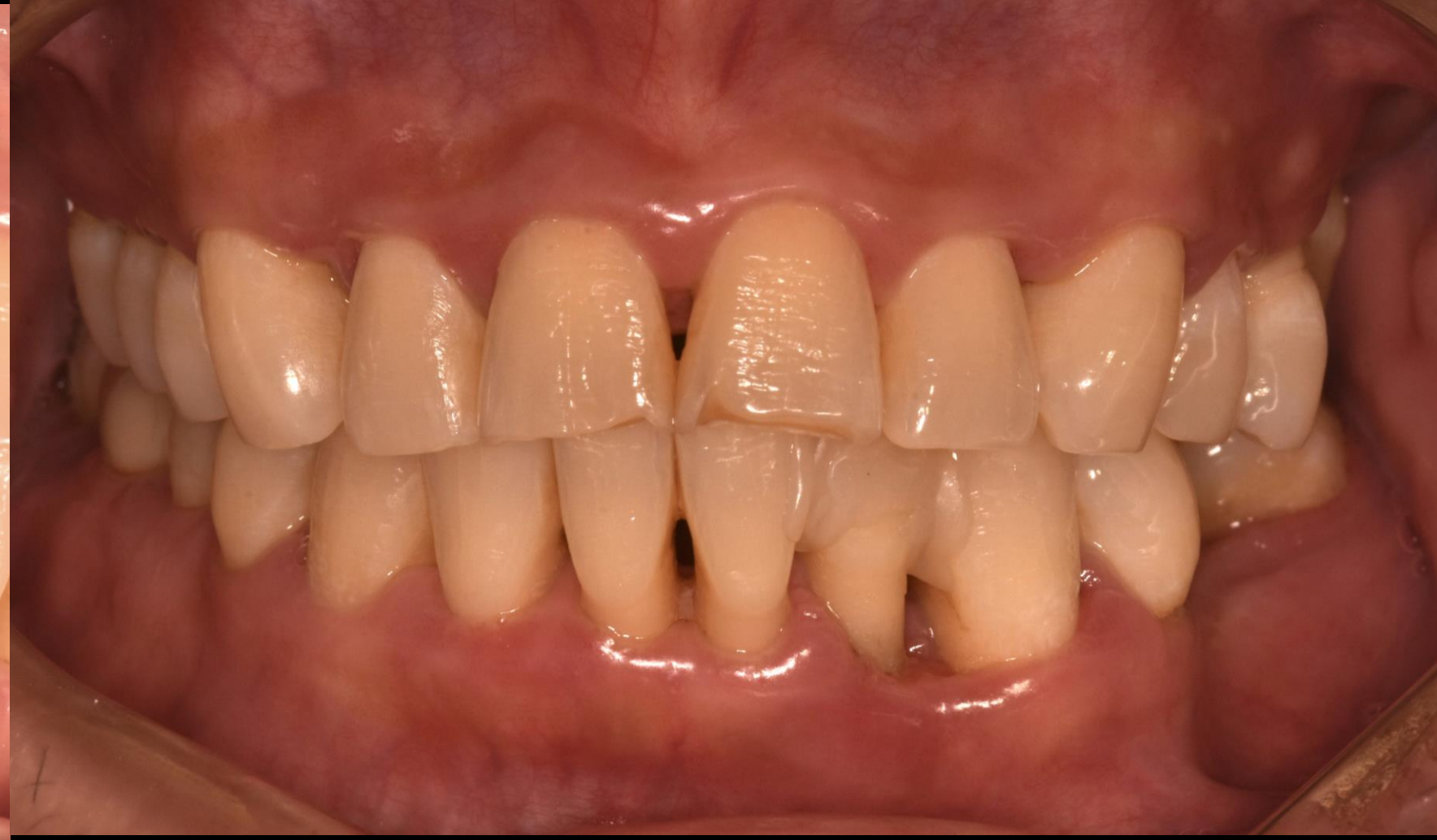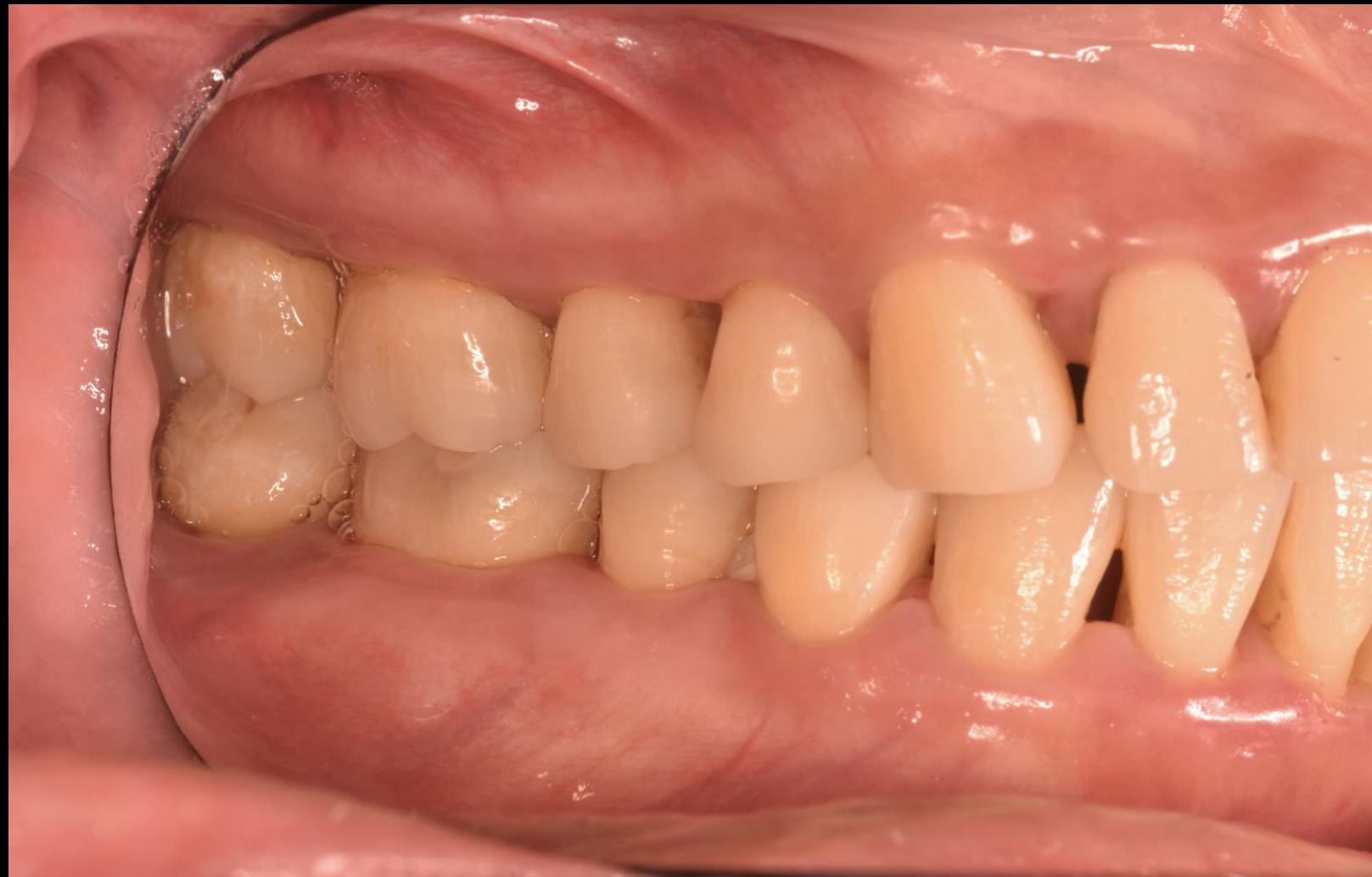- Pathosis and diagnosis

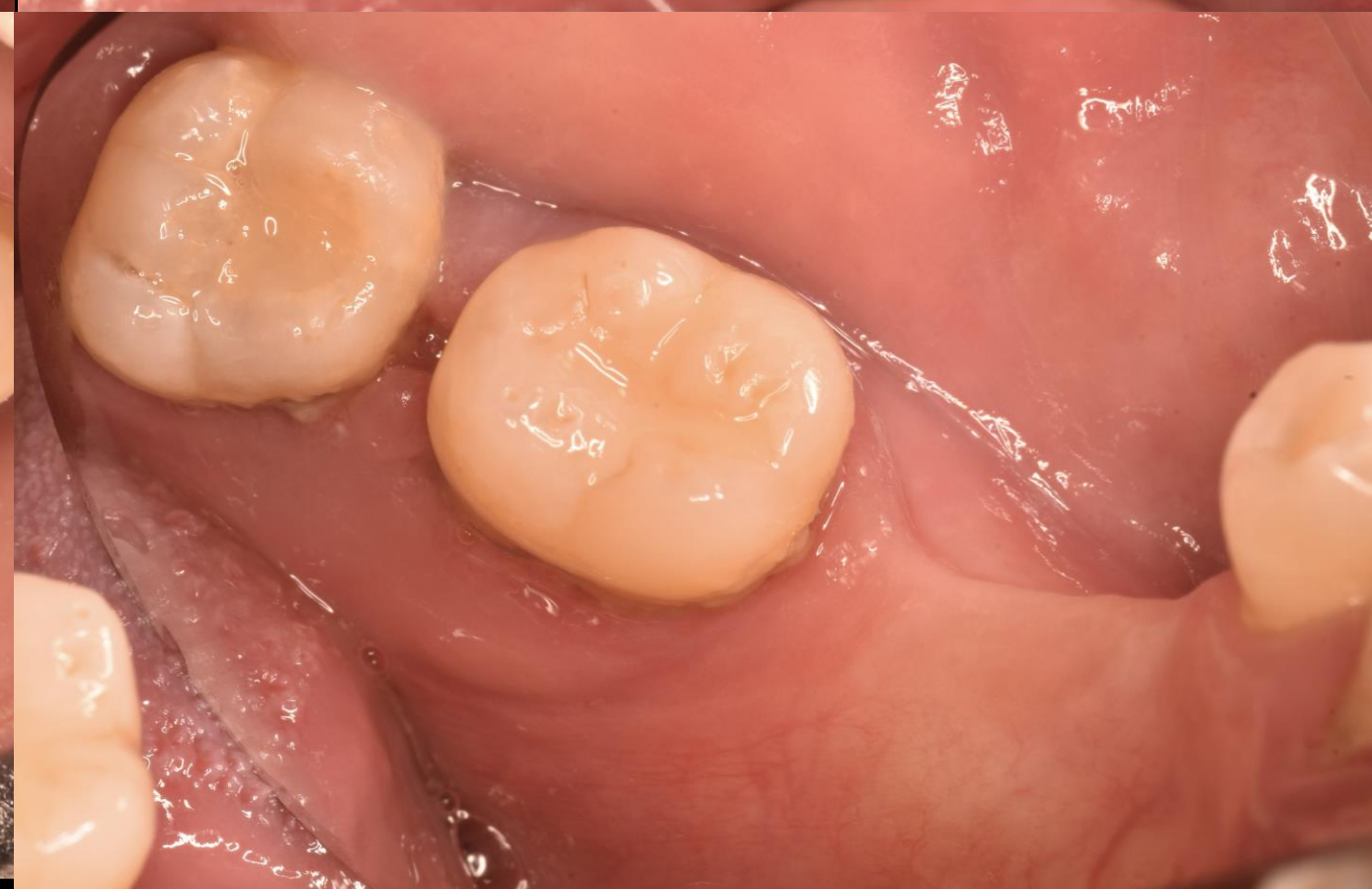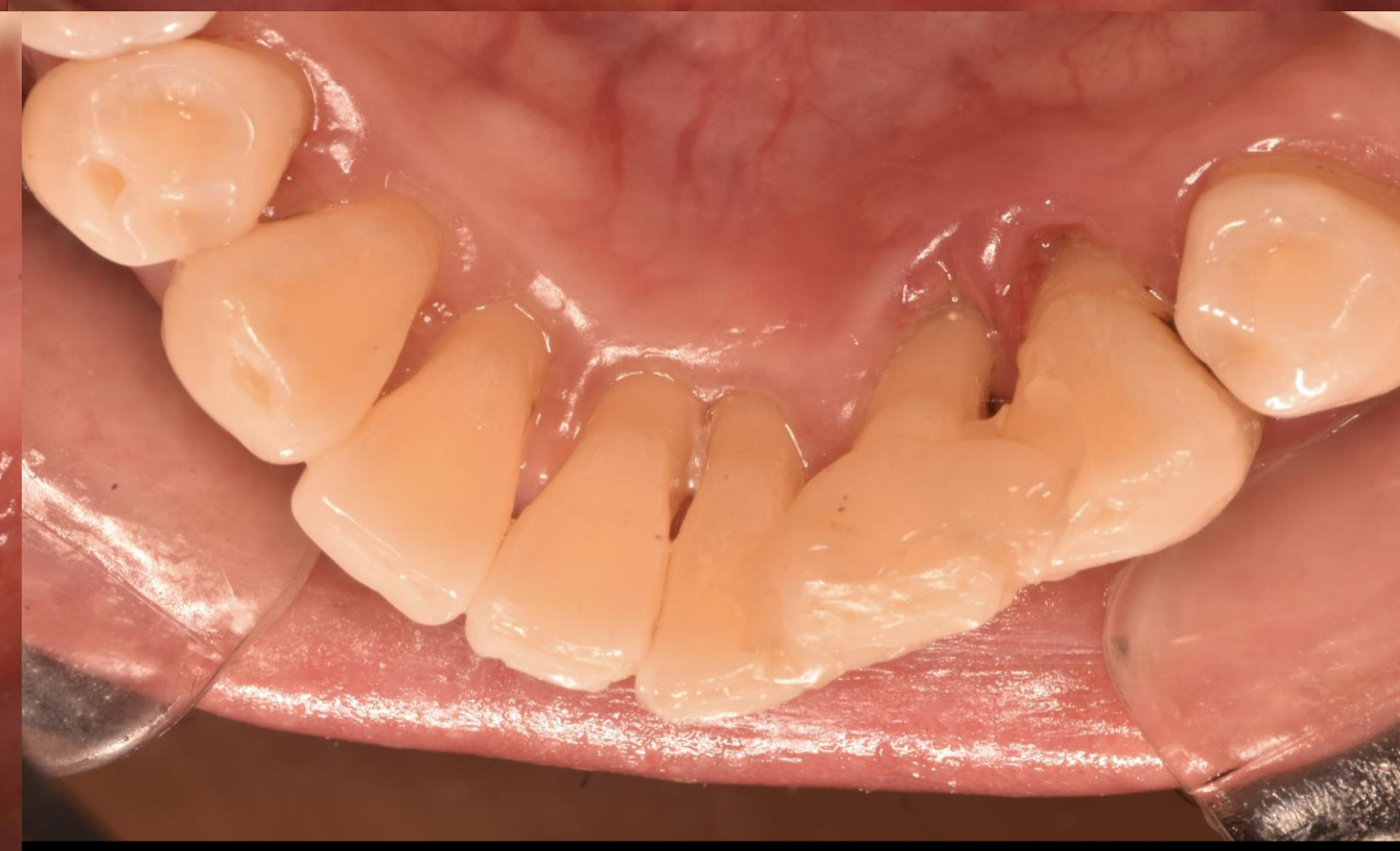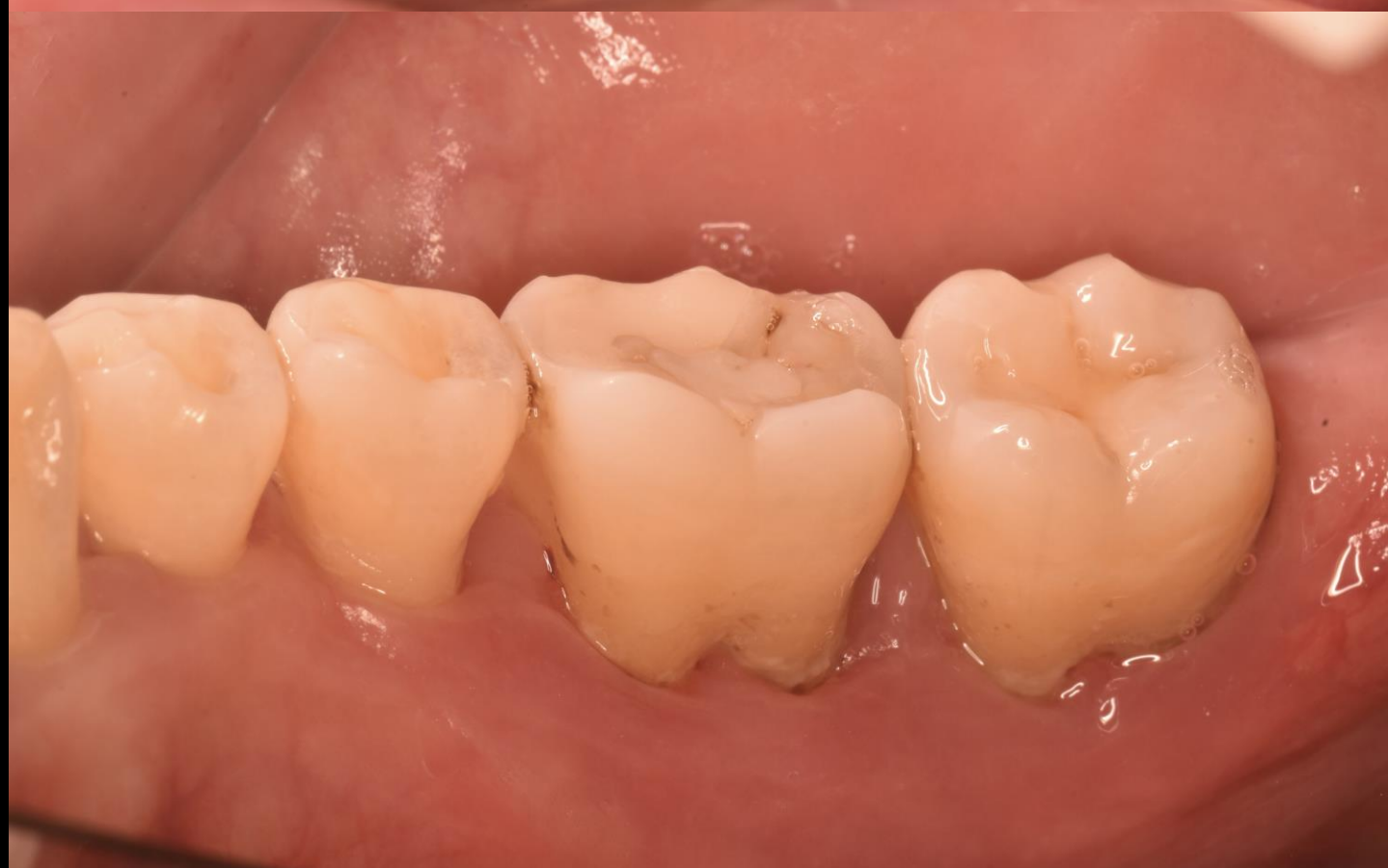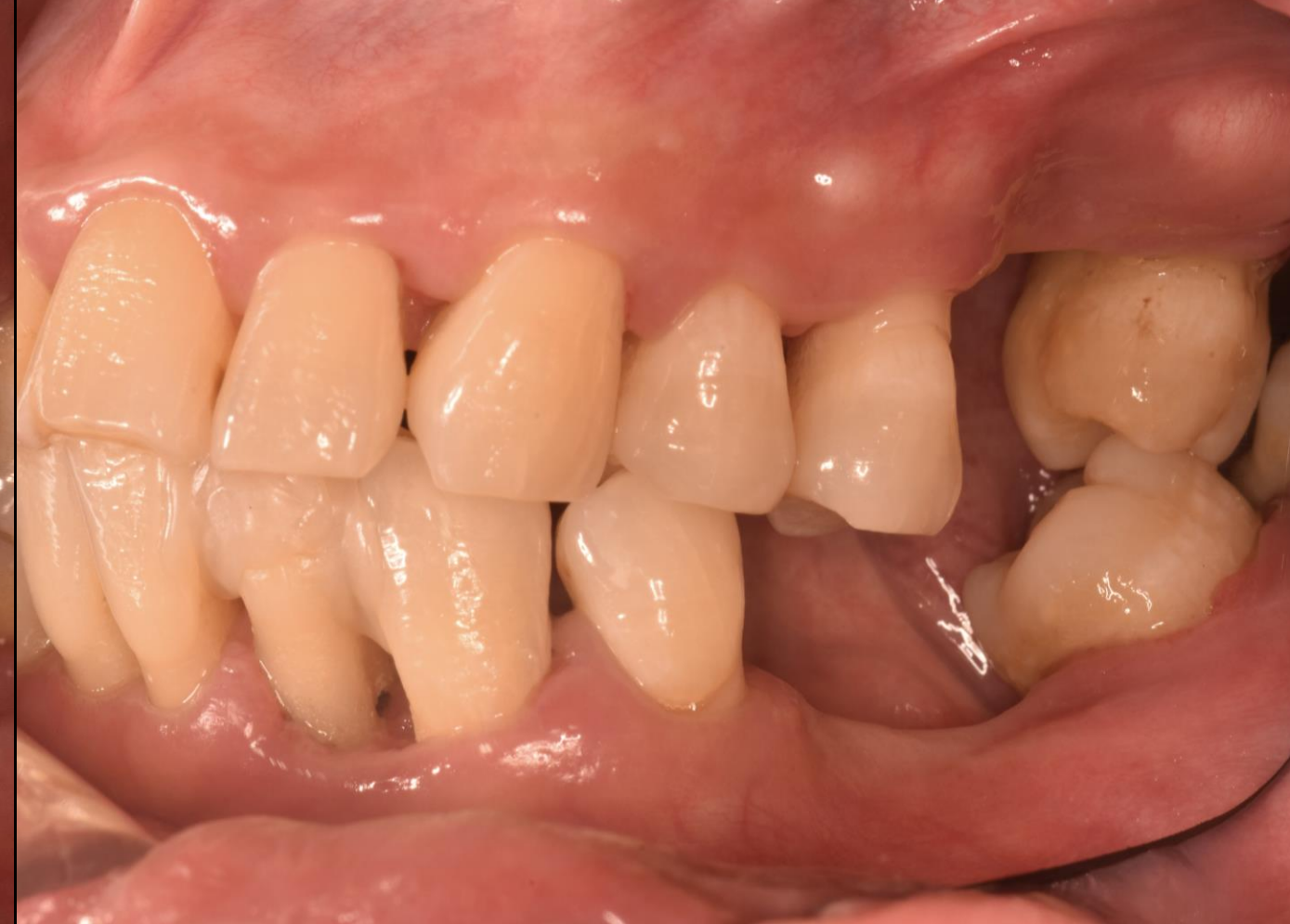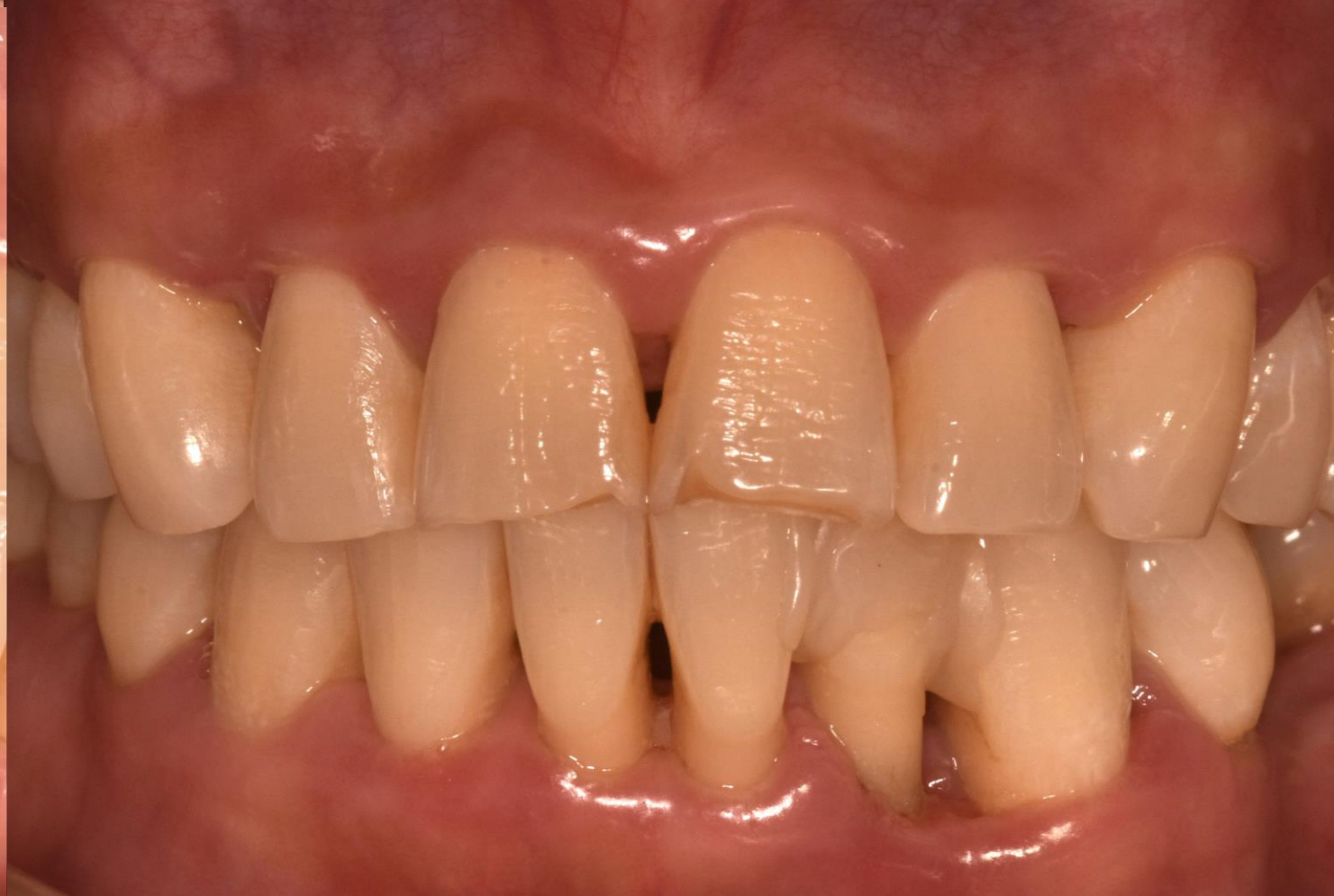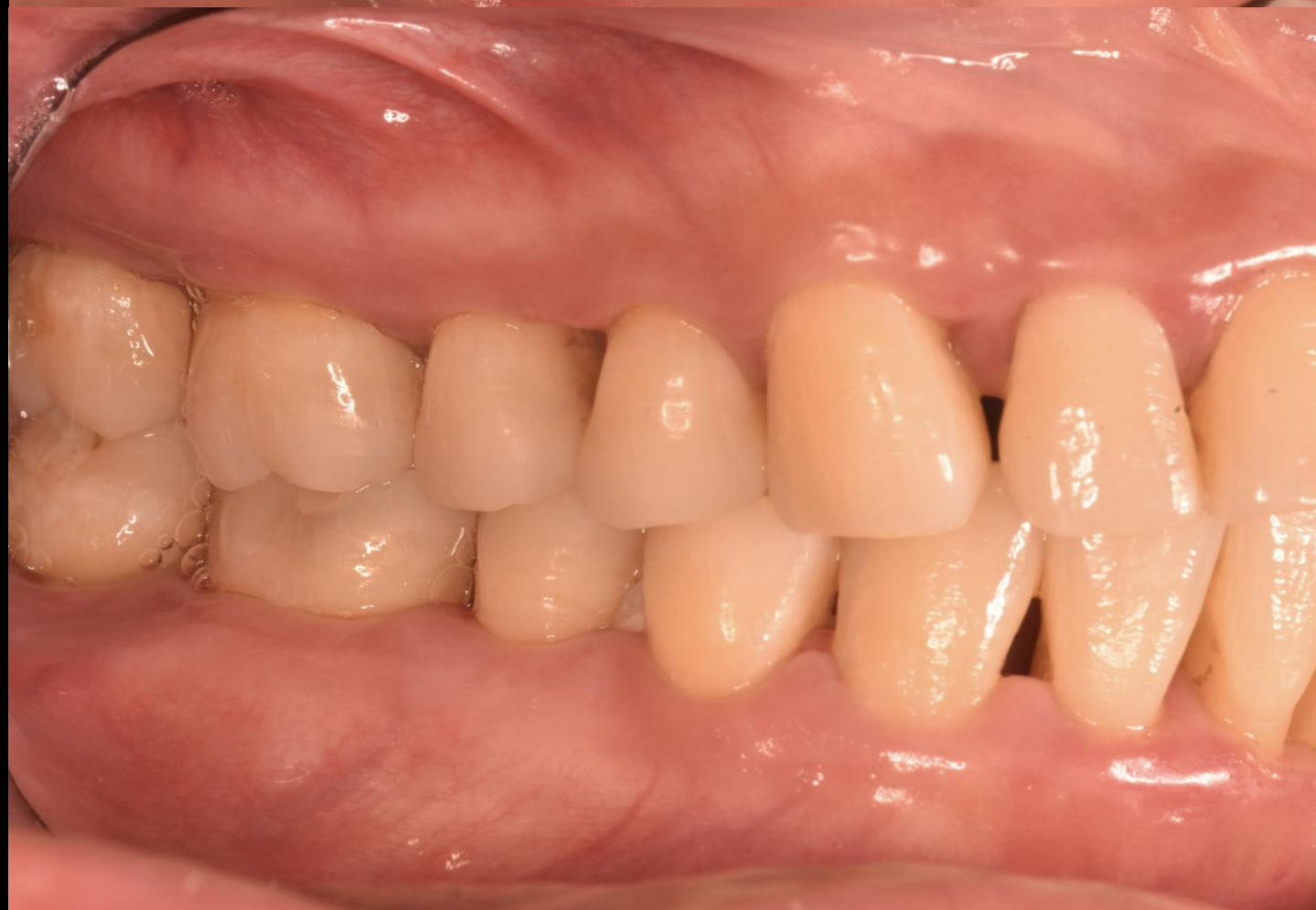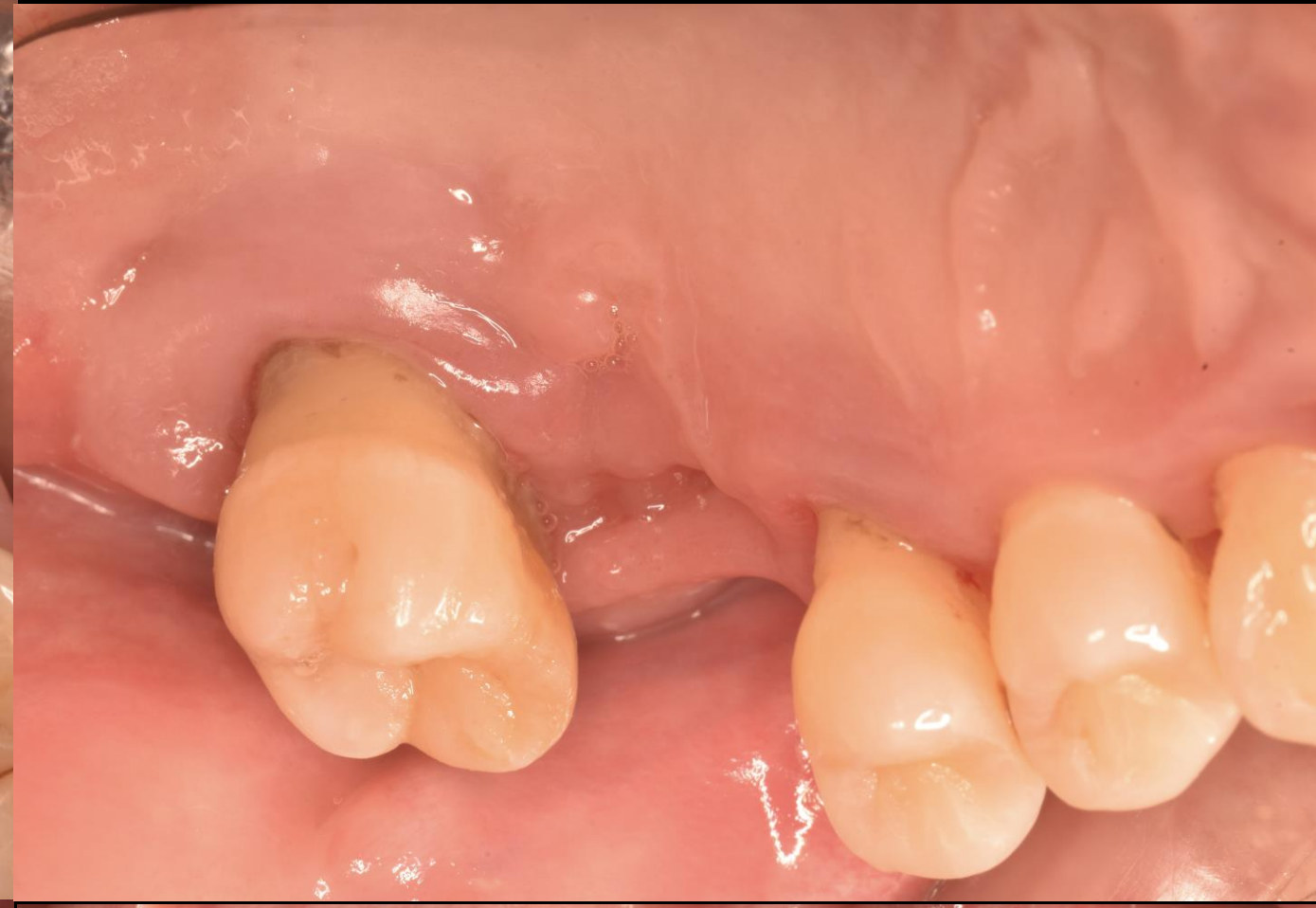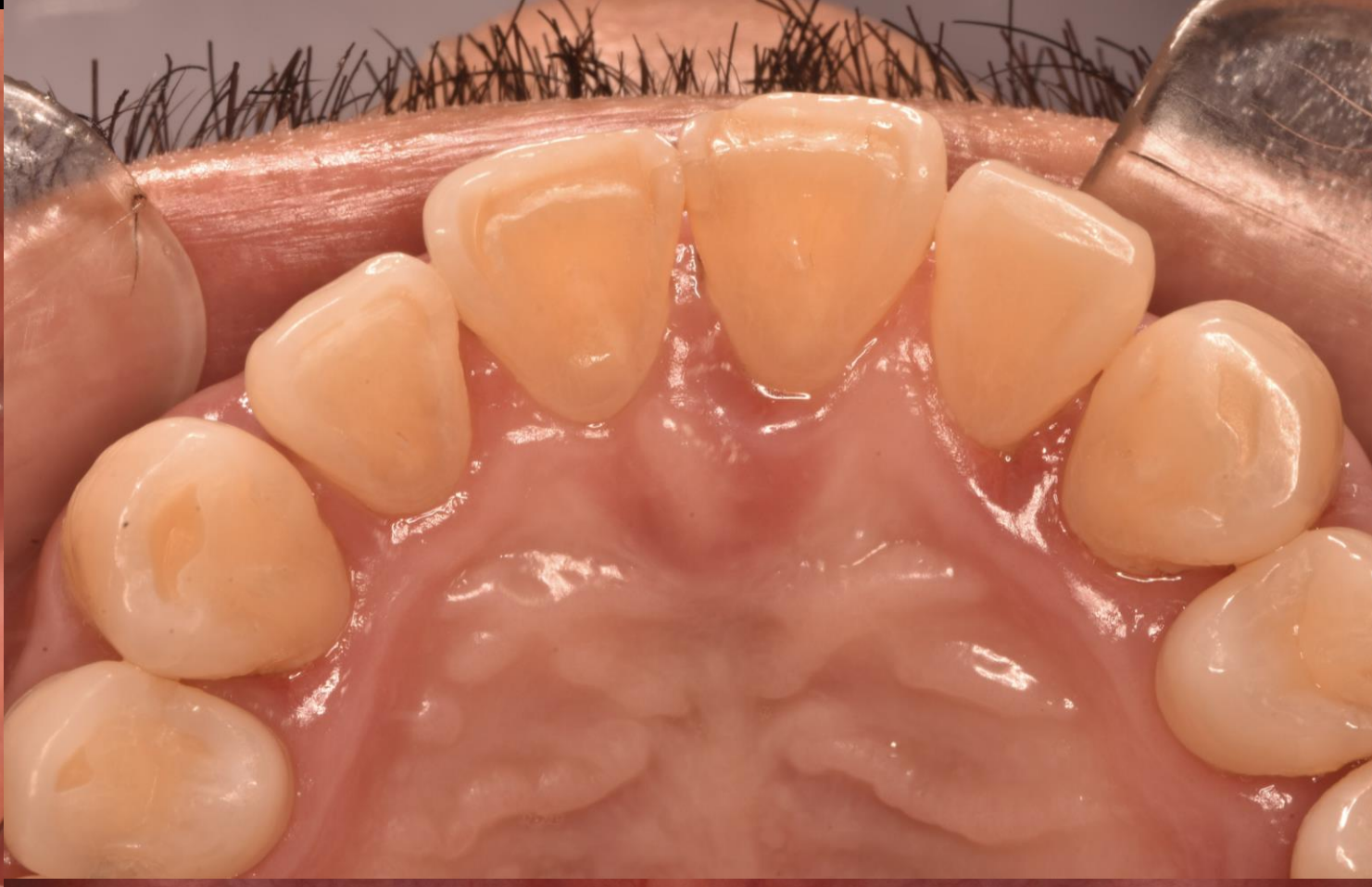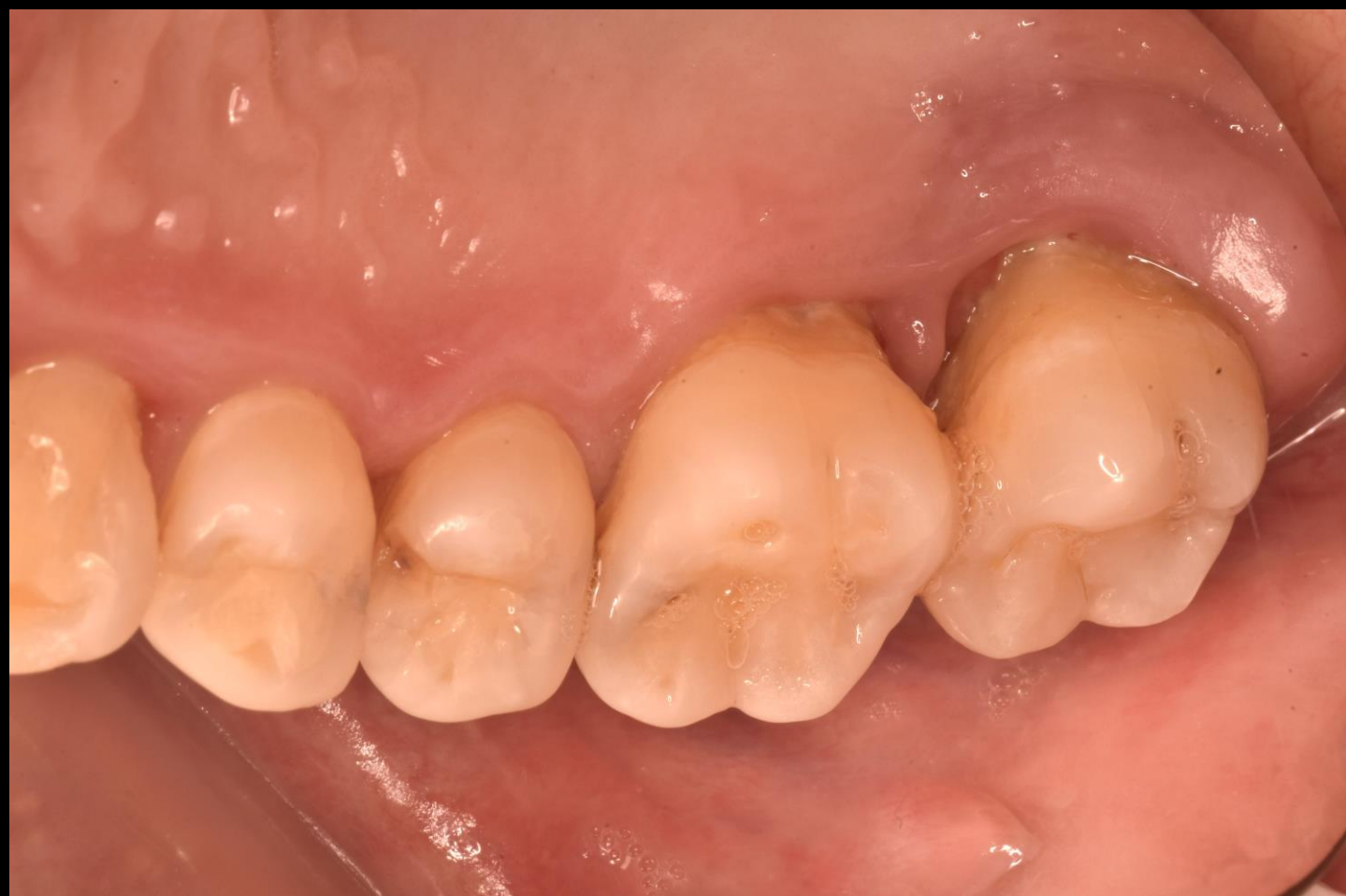EXTRA ORAL SMILE PICTURES



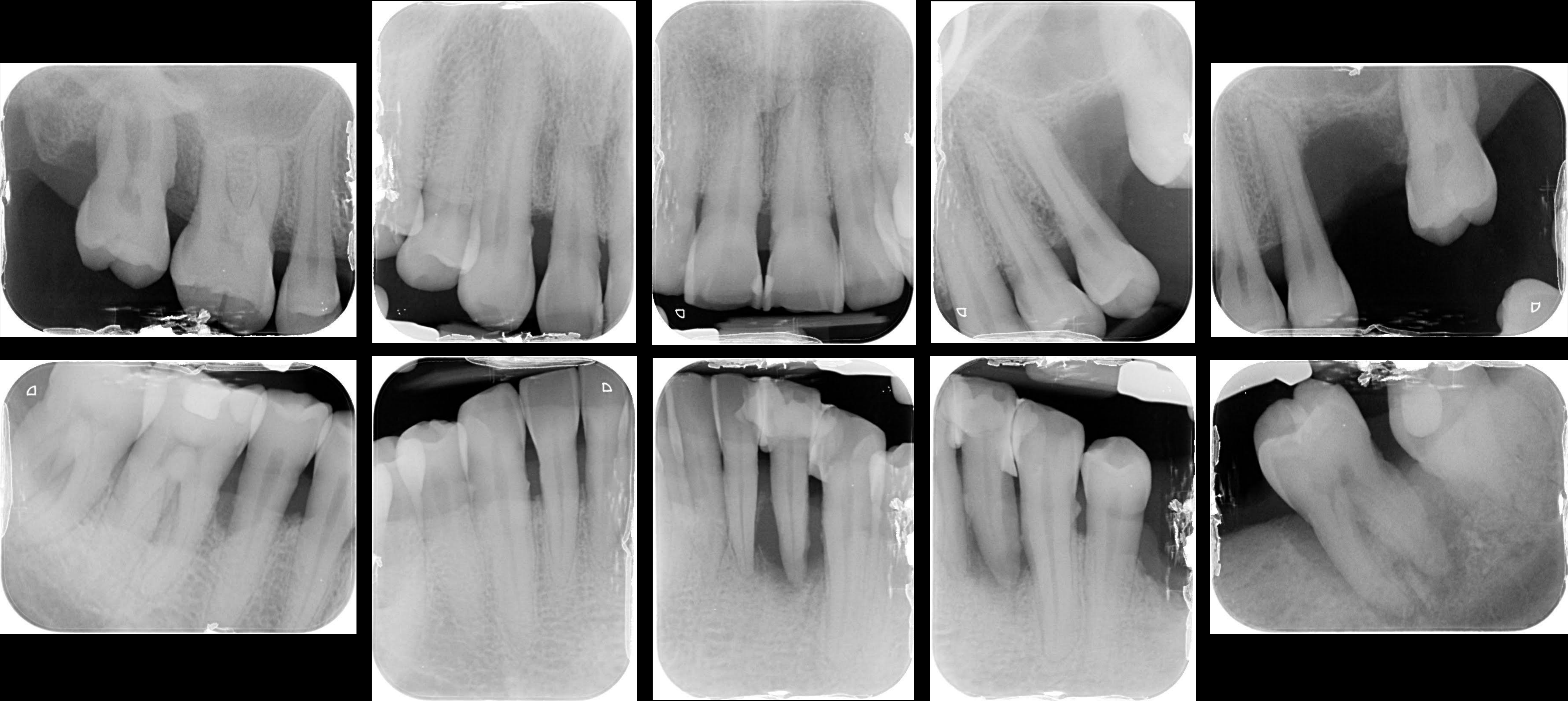
(AT REST EXTRAORAL WILL ONLY BE NEEDED IF IT IS PERTINENT TO THE CASE)_

INTRA-ORAL OVERALL VIEWS





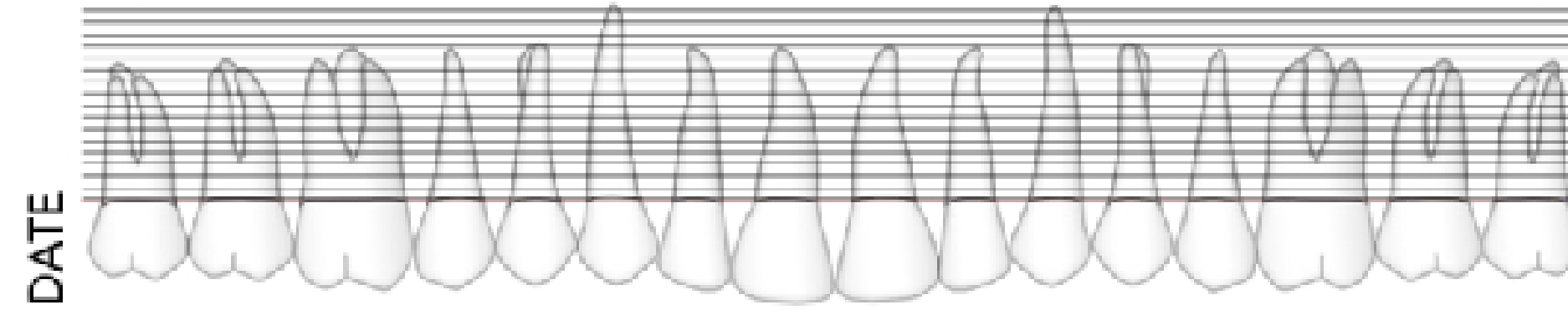
**FULL MOUTH PERIAPICAL RADIOGRAPHS
PLEASE INCLUDE POSTERIOR BITE WINGS**



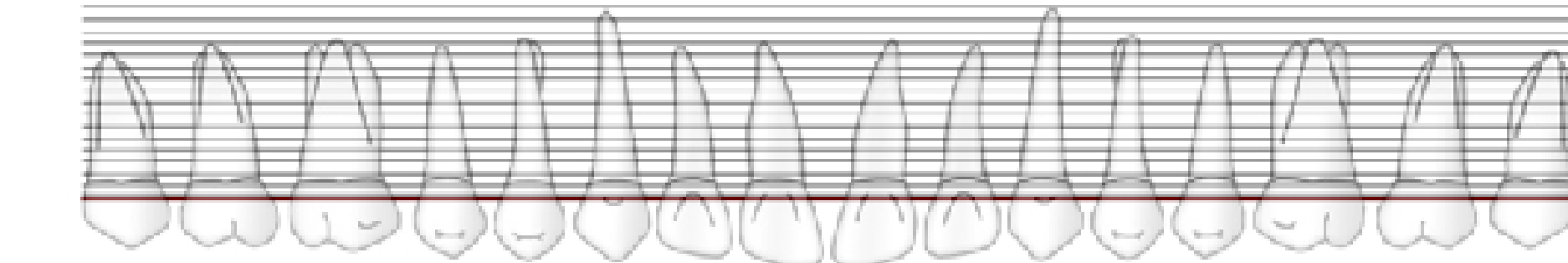
COMPLETE PERIODONTAL CHARTING

PHILIPPINE BOARD OF PERIODONTOLOGY

CAL															
Facial Gingival Recession															
Subcal Probing Depth															
18	17	16	15	14	13	12	11	21	22	23	24	25	26	27	28

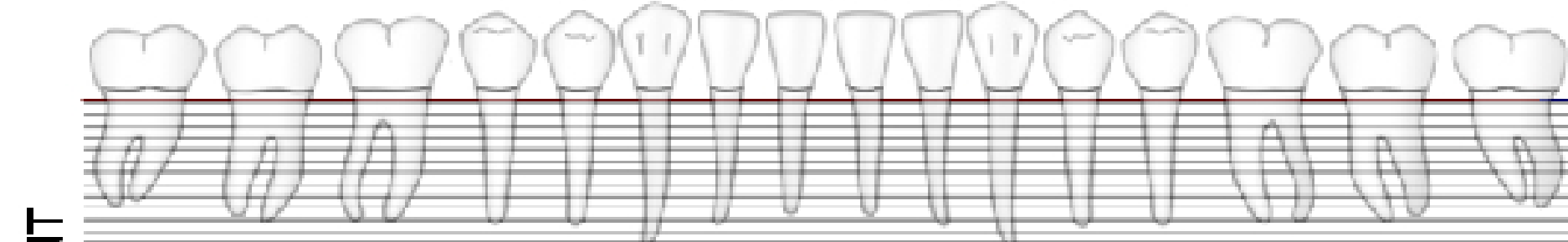


CAL															
Lingual Gingival Recession															
Lingual Probing Depth															
18	17	16	15	14	13	12	11	21	22	23	24	25	26	27	28

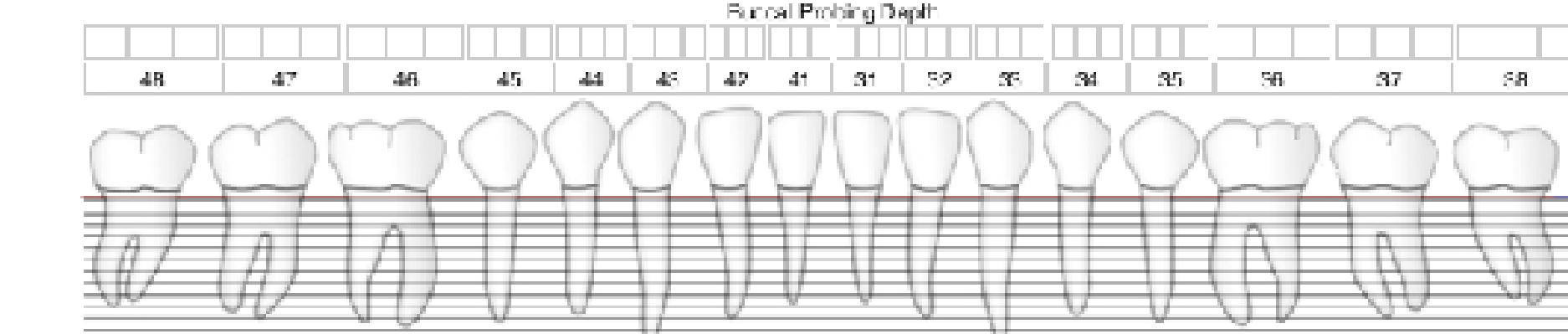


Copyright: DENTAL LOGICS

CAL															
Lingual Gingival Recession															
Lingual Probing Depth															
48	47	46	45	44	43	42	41	31	32	33	34	35	36	37	38



CAL															
Facial Gingival Recession															
Facial Probing Depth															
48	47	46	45	44	43	42	41	31	32	33	34	35	36	37	38



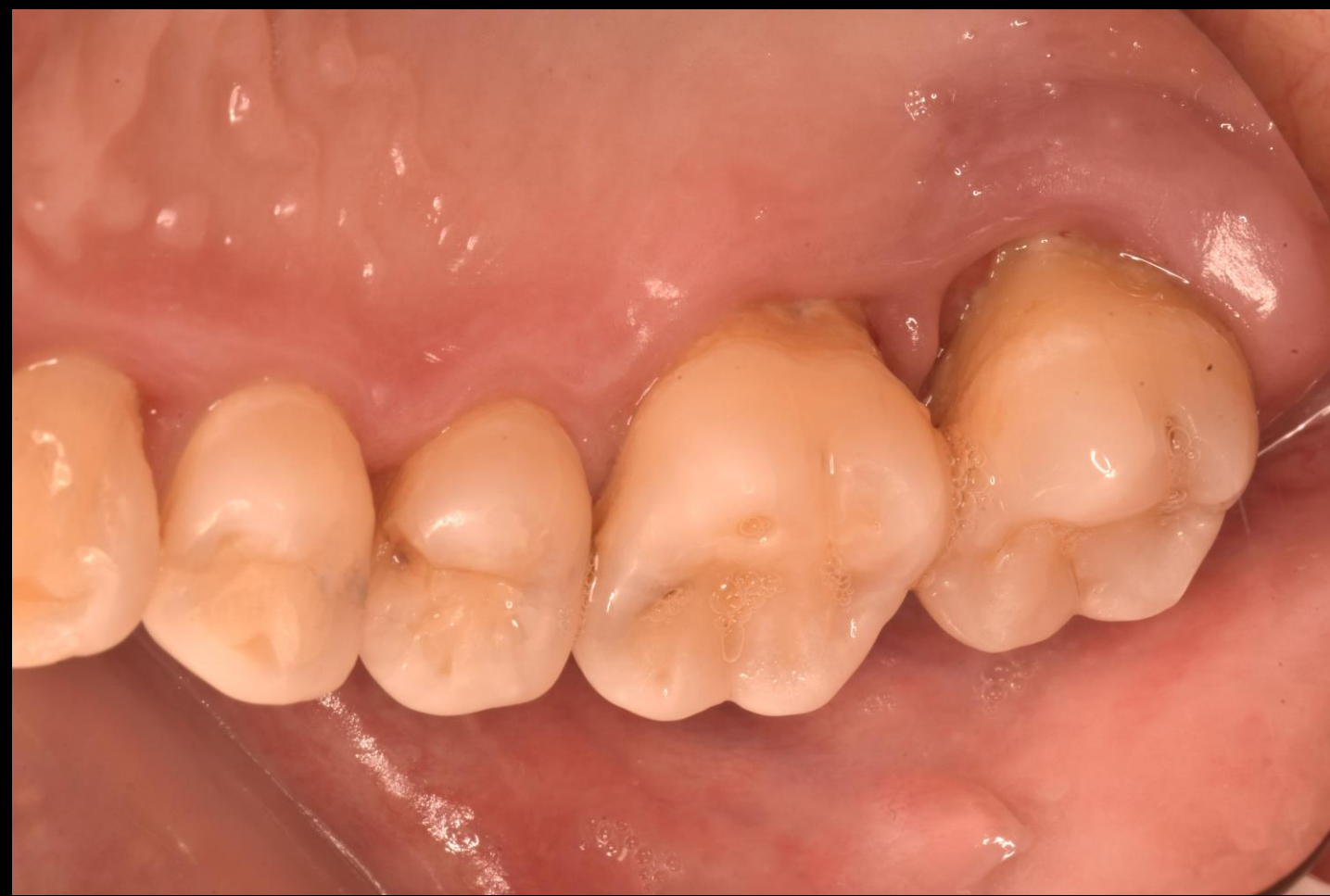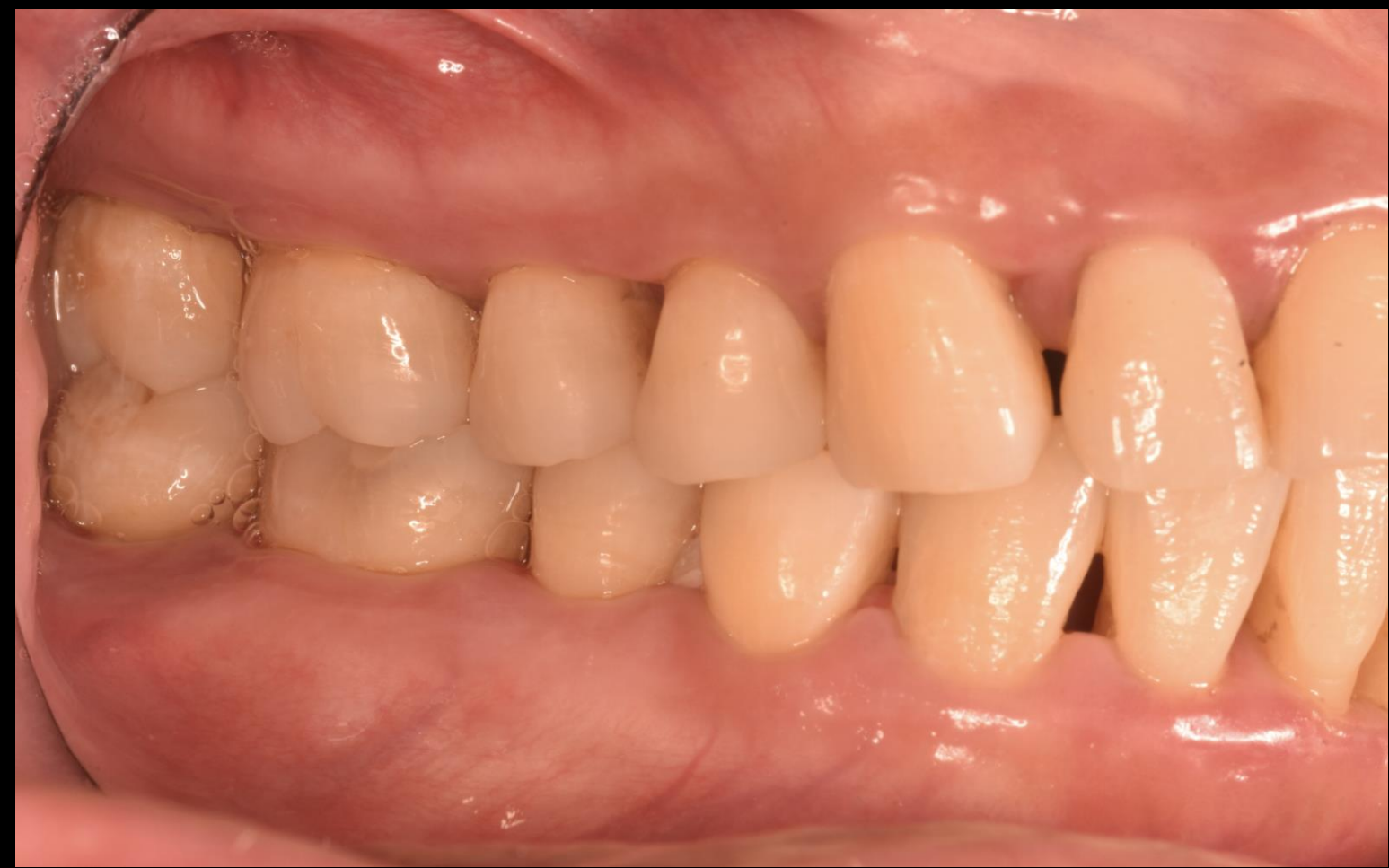PHOTOS OF THE STUDY CASTS

RIGHT LATERAL OCCLUSION

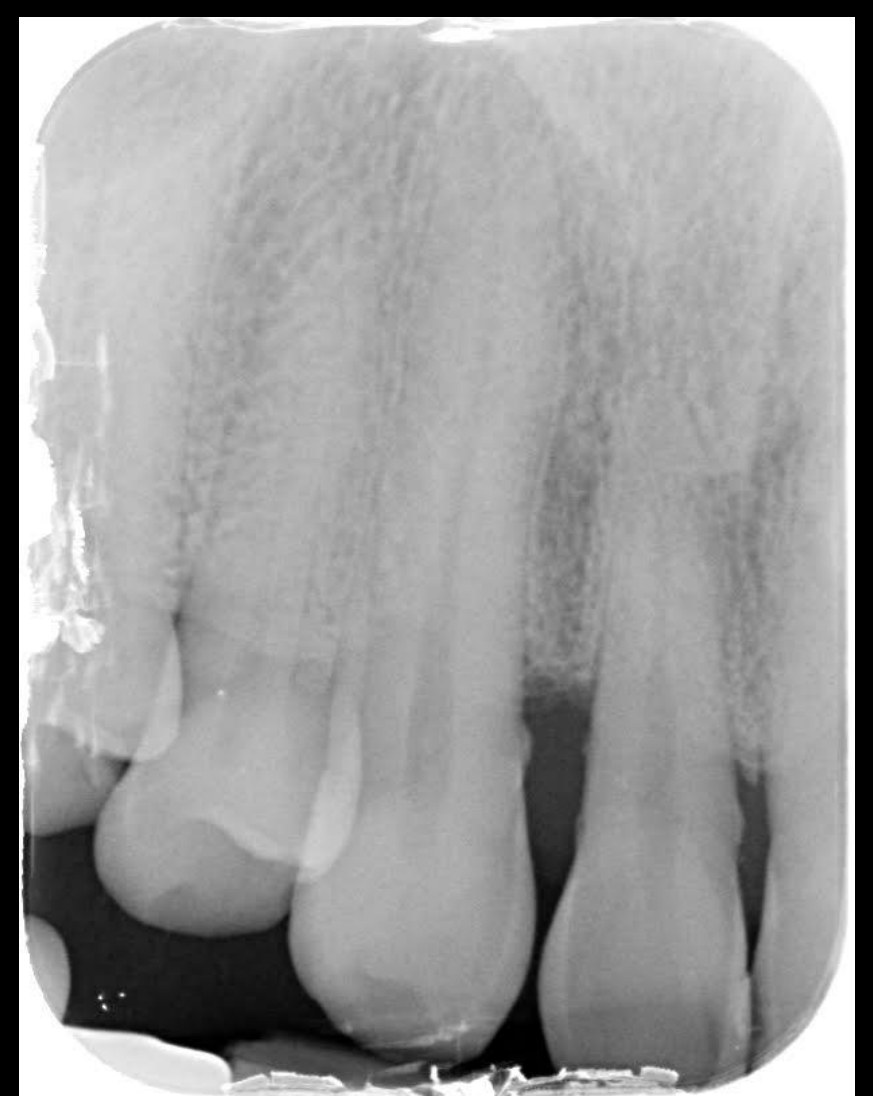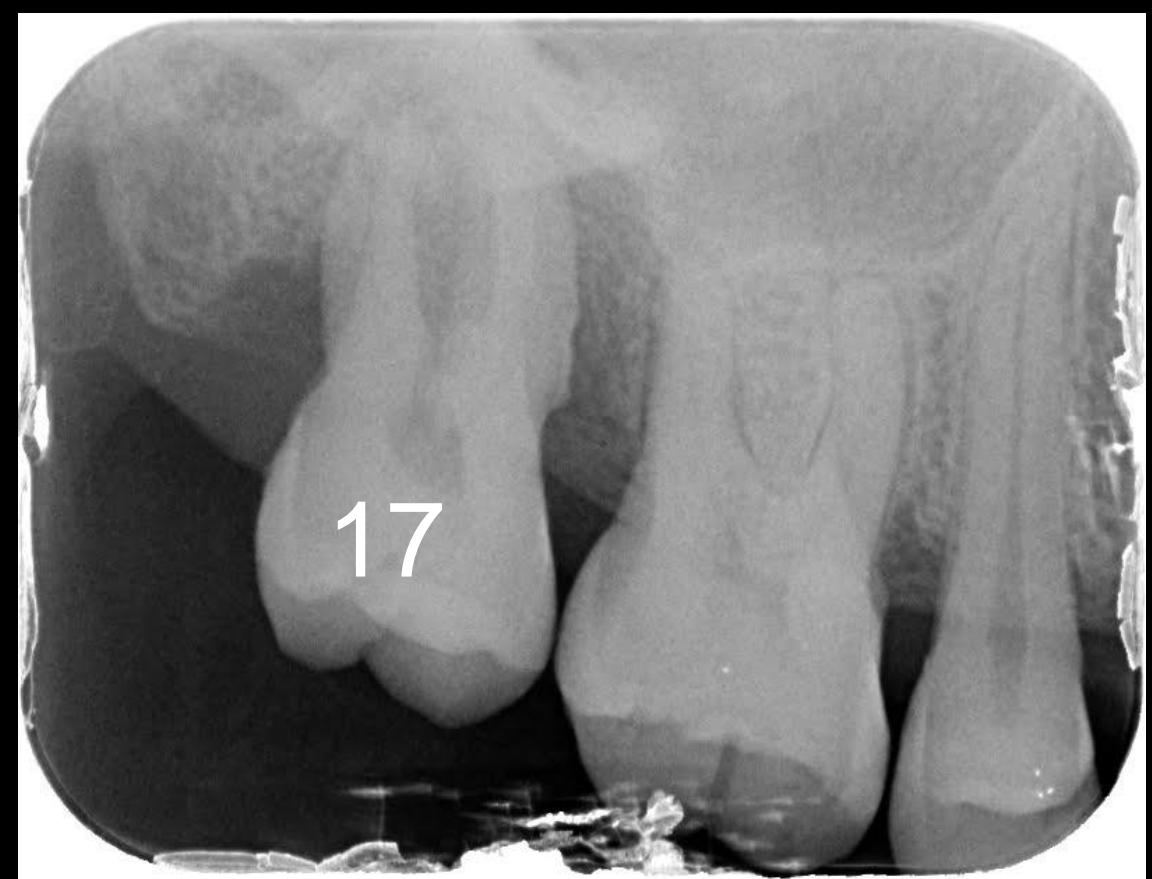FRONT
IN OCCLUSION

LEFT LATERAL OCCLUSION

UPPER RIGHT QUADRANT

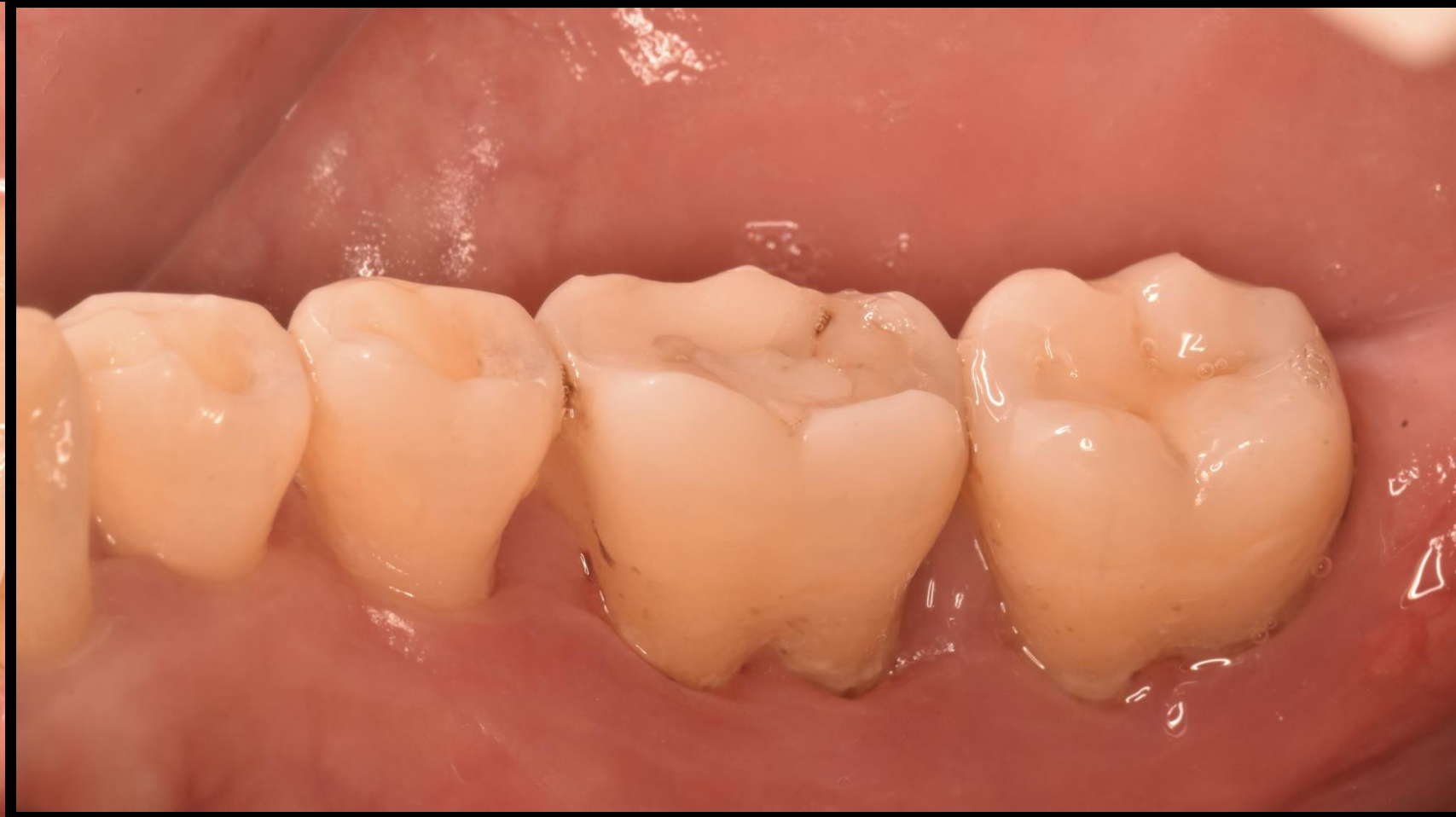
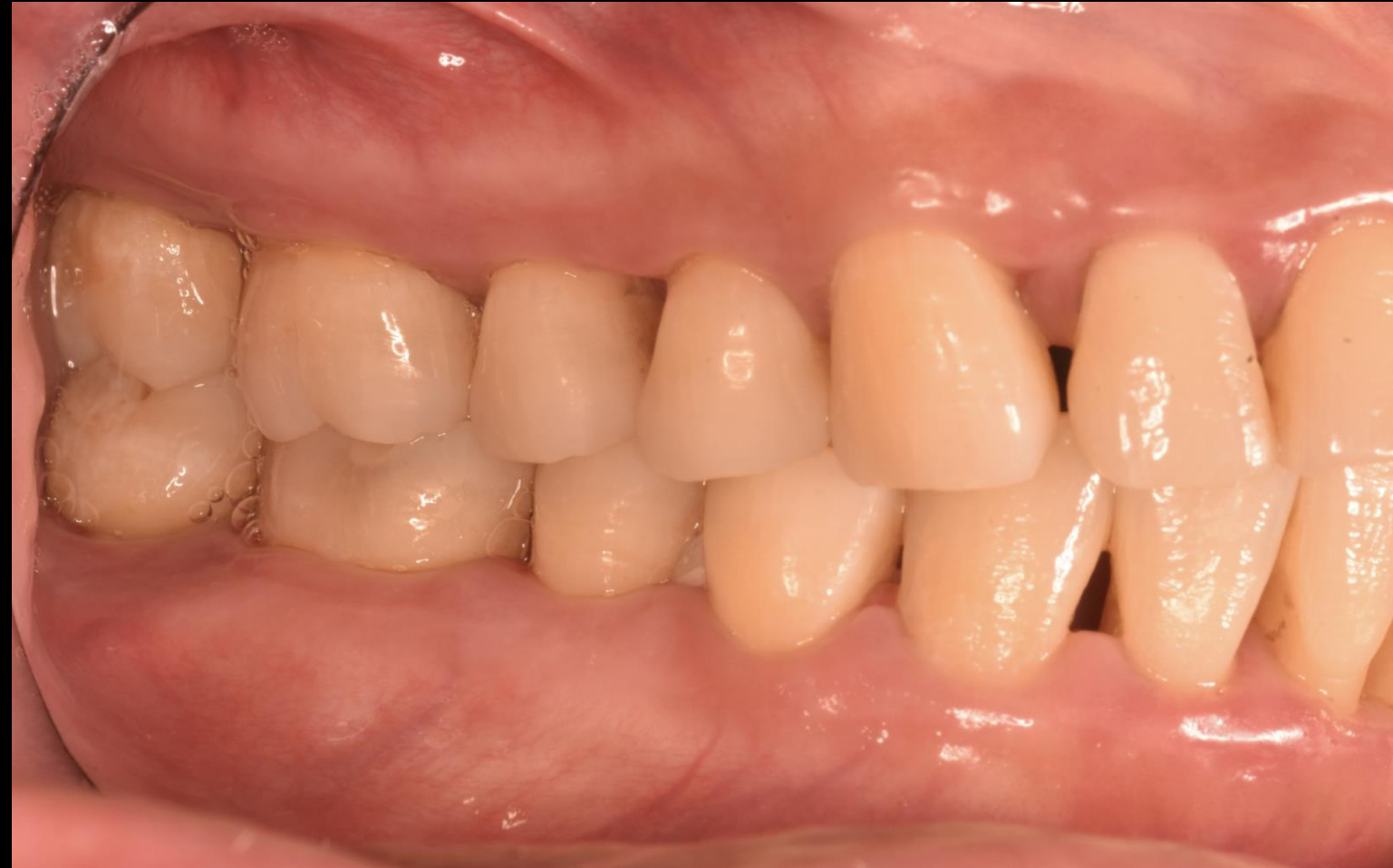
PLEASE PUT CHARTING
HERE

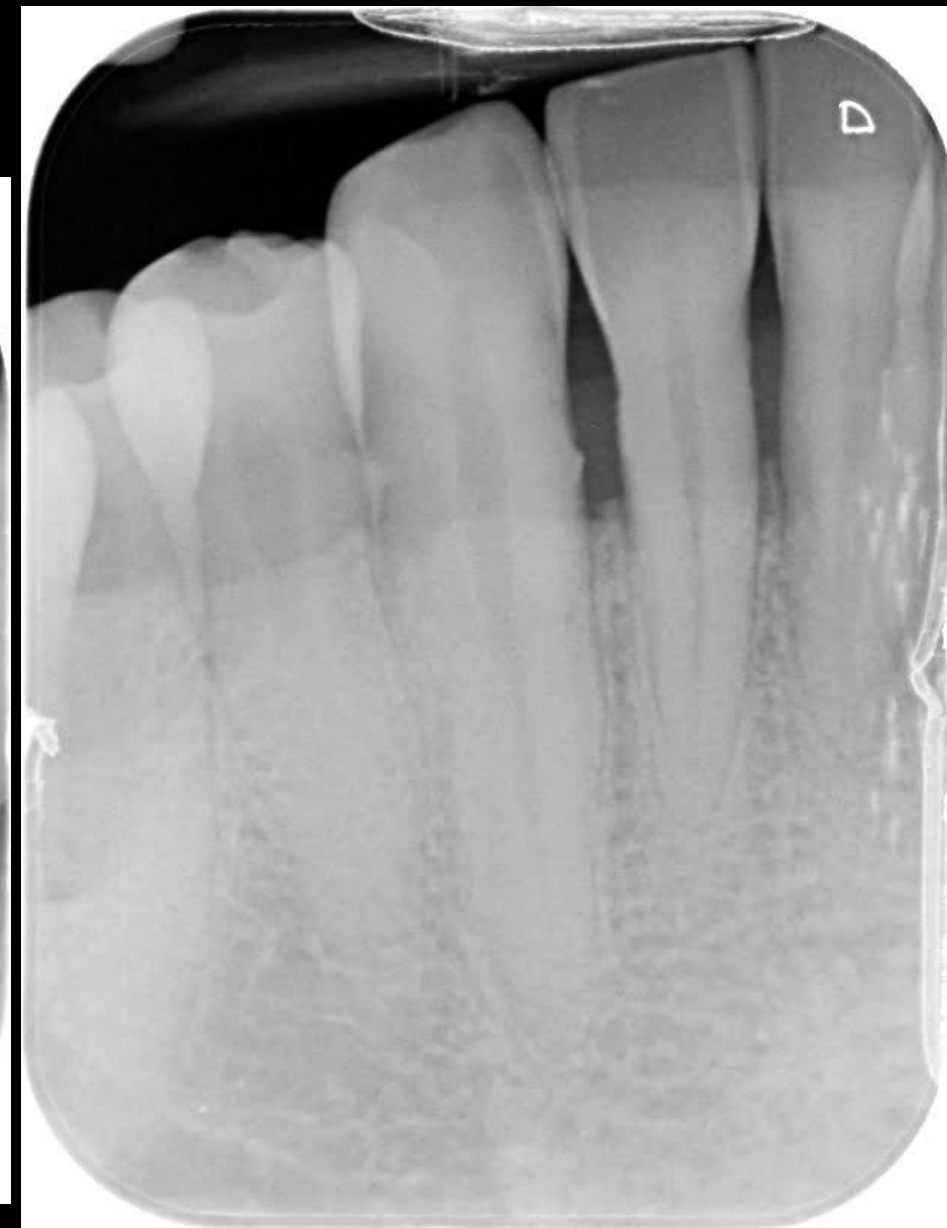
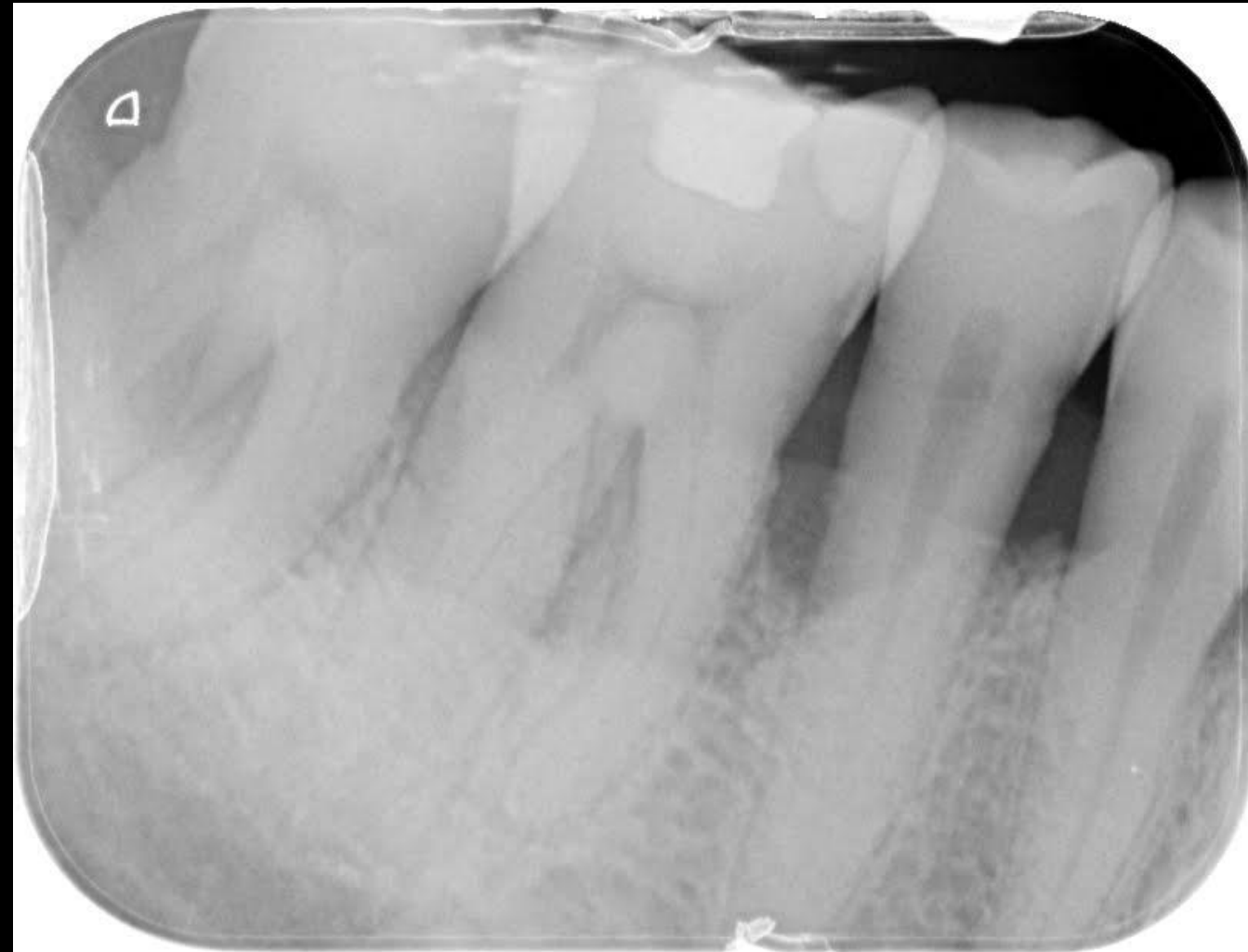
DESCRIPTION OF
THE CASE

LOWER RIGHT QUADRANT



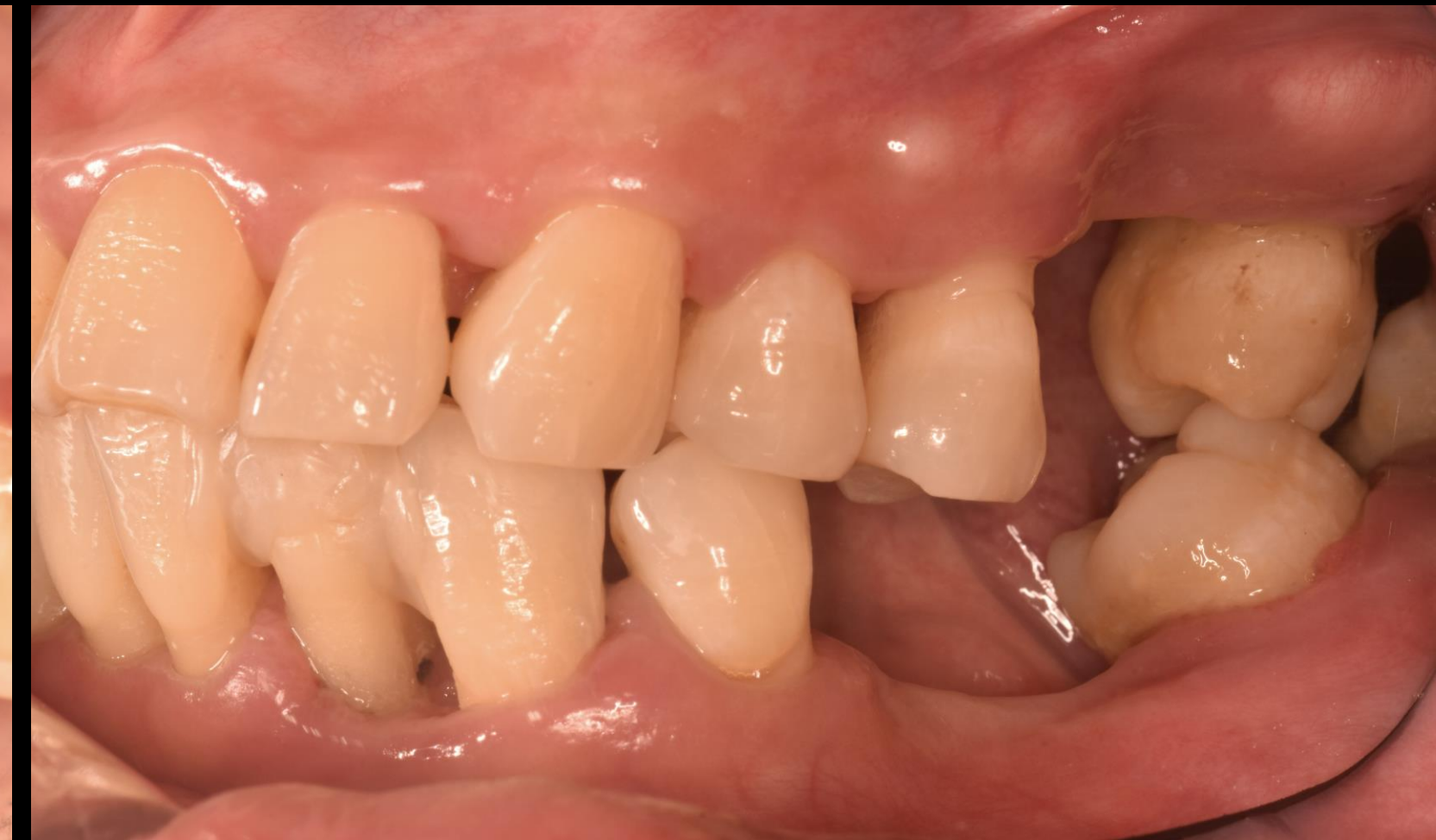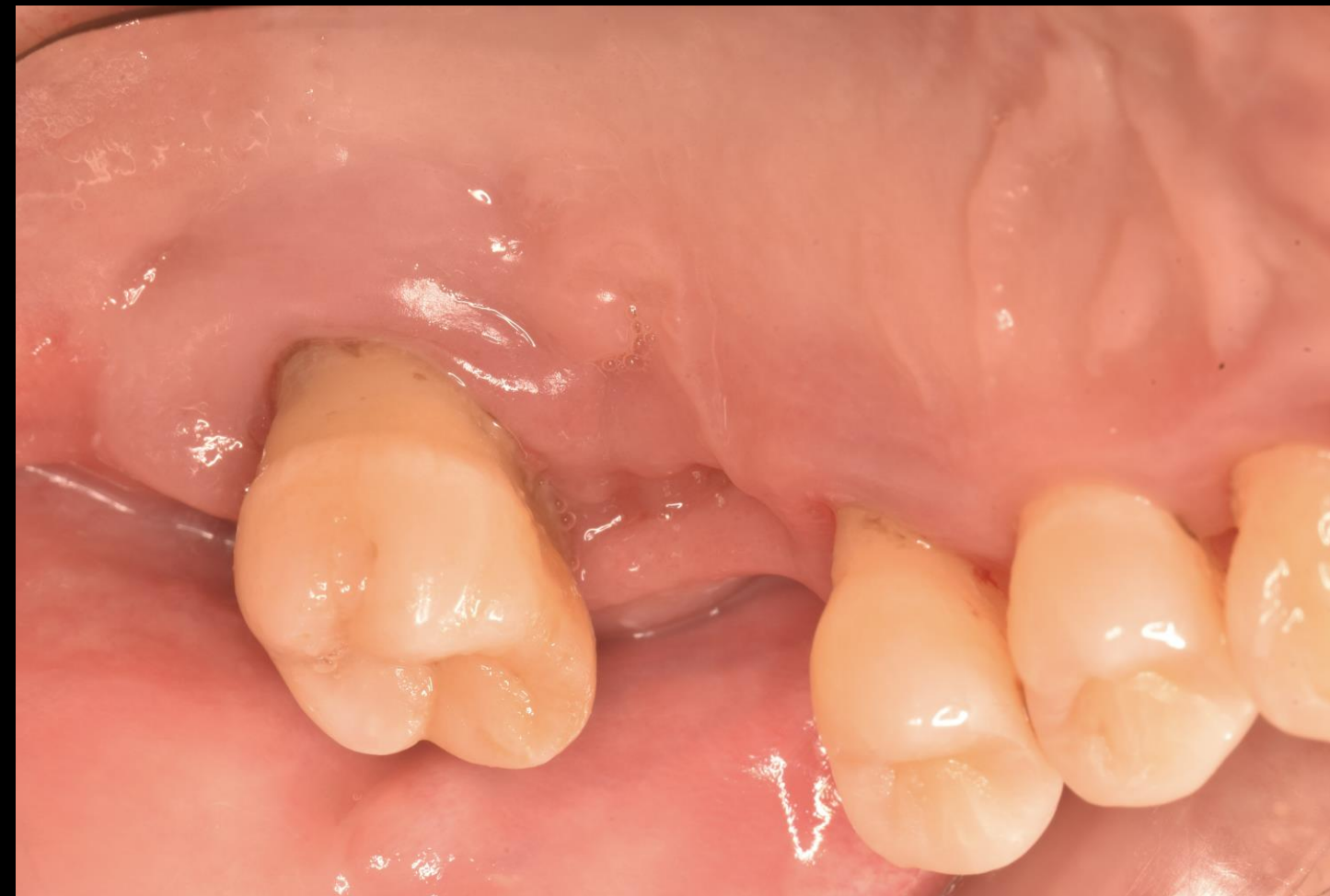PLEASE PUT CHARTING
HERE



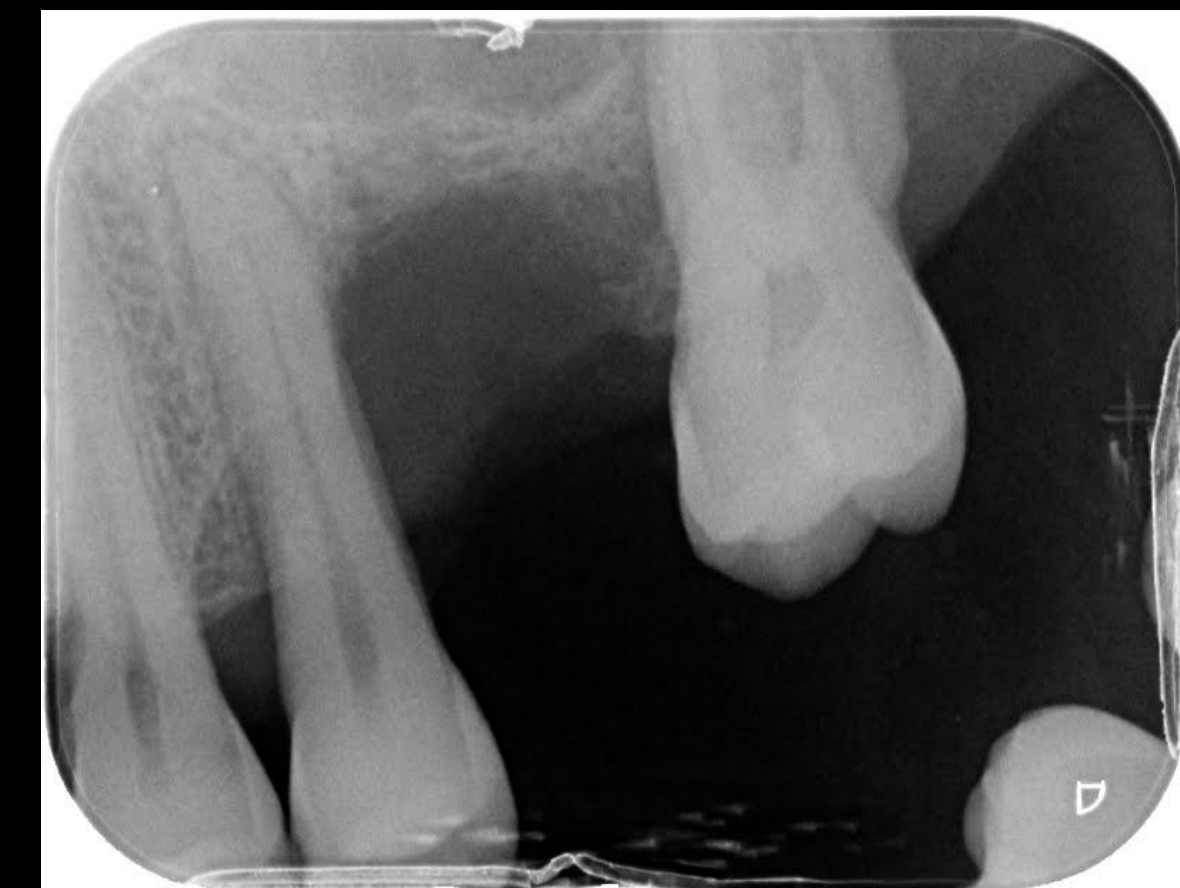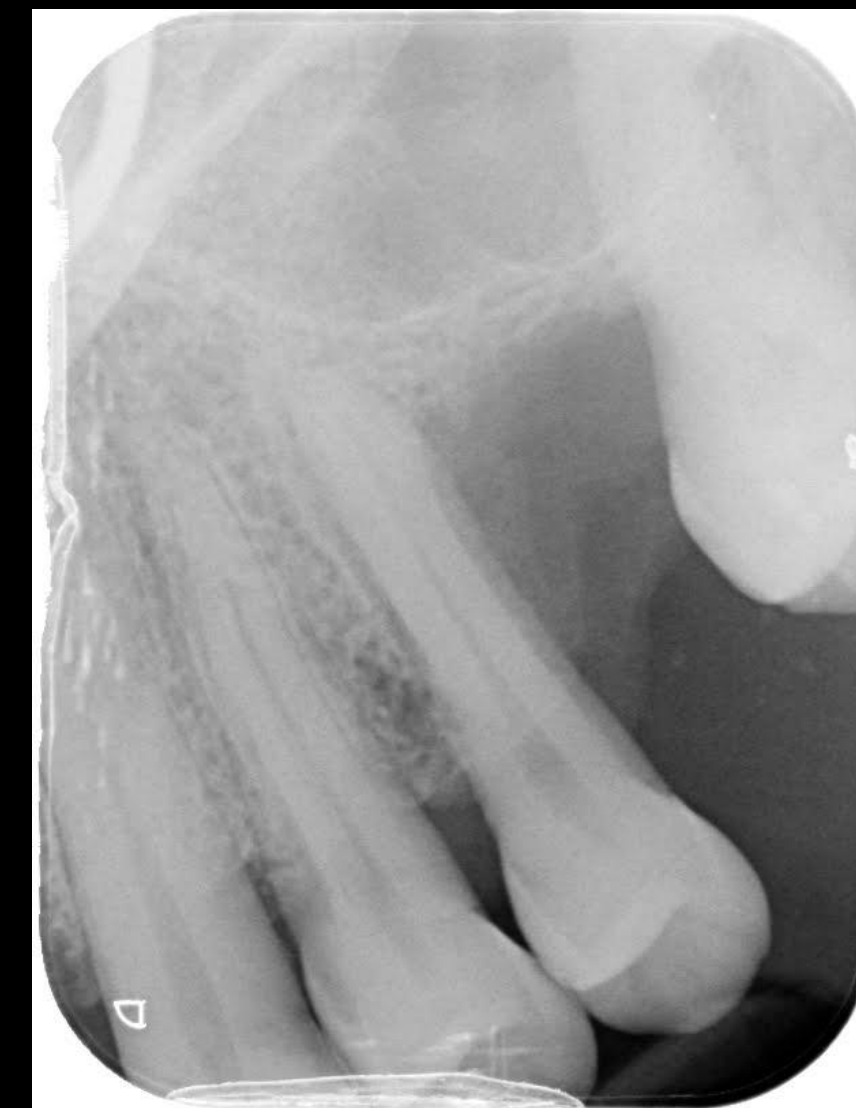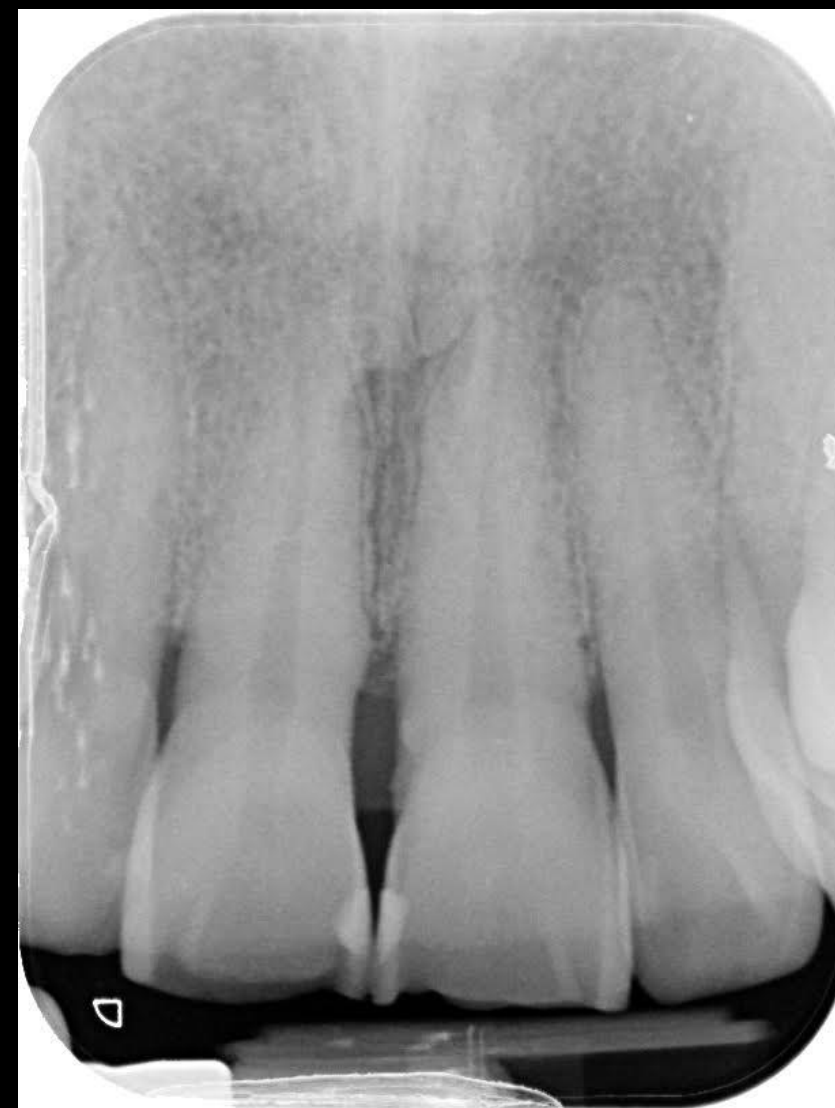DESCRIPTION OF THE CASE

UPPER LEFT QUADRANT

PLEASE PUT CHARTING
HERE

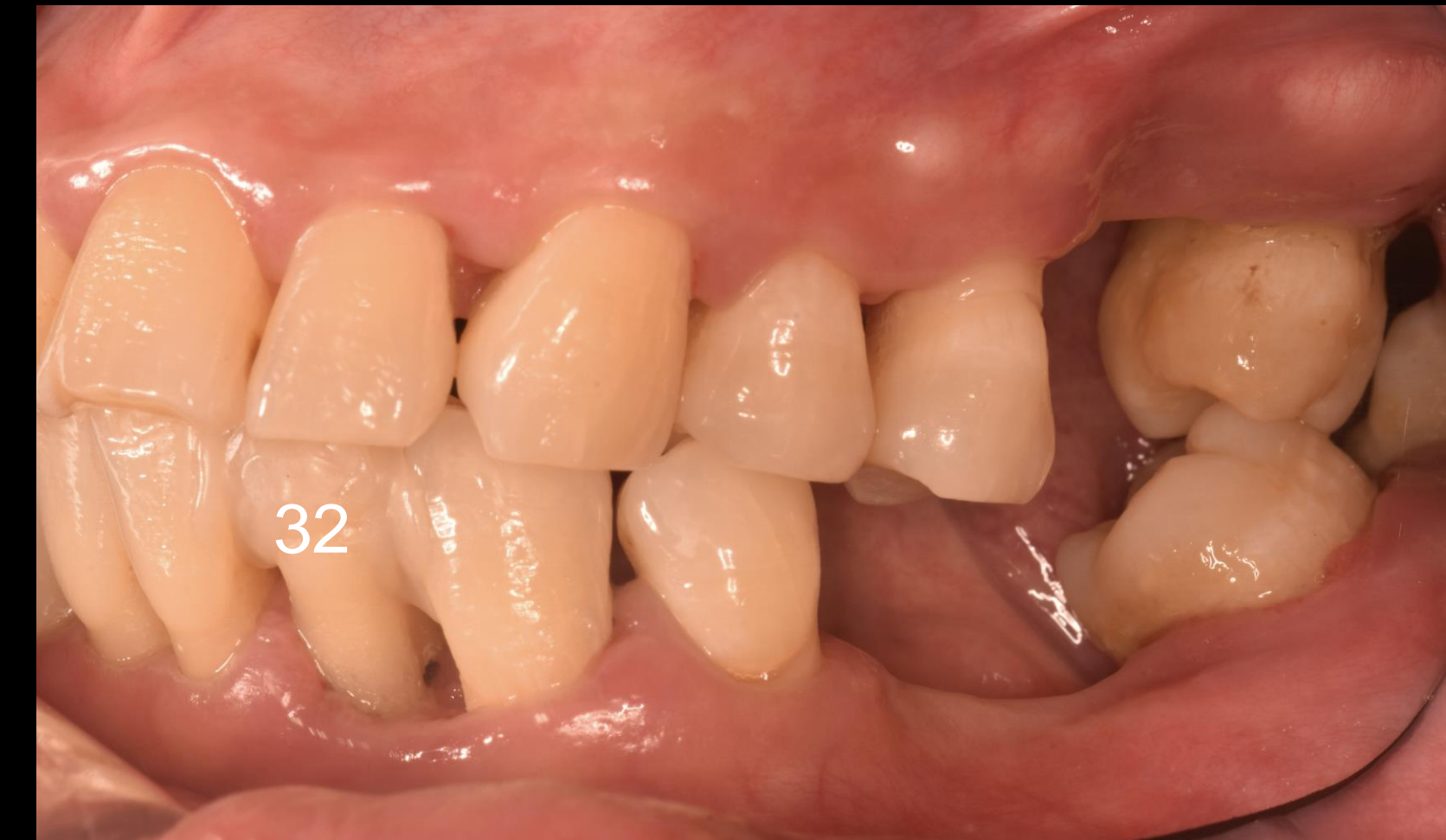
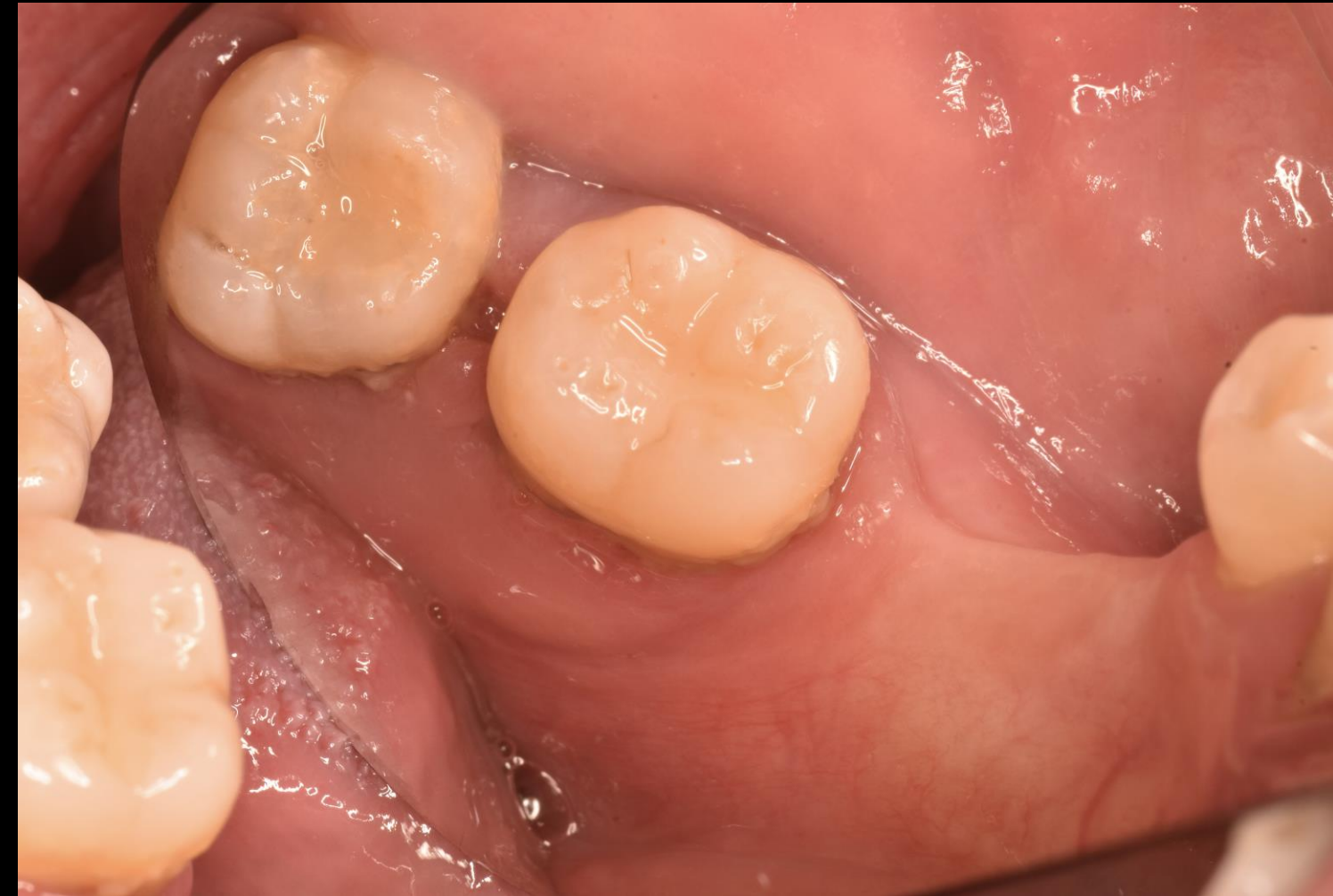
DESCRIPTION OF
THE CASE

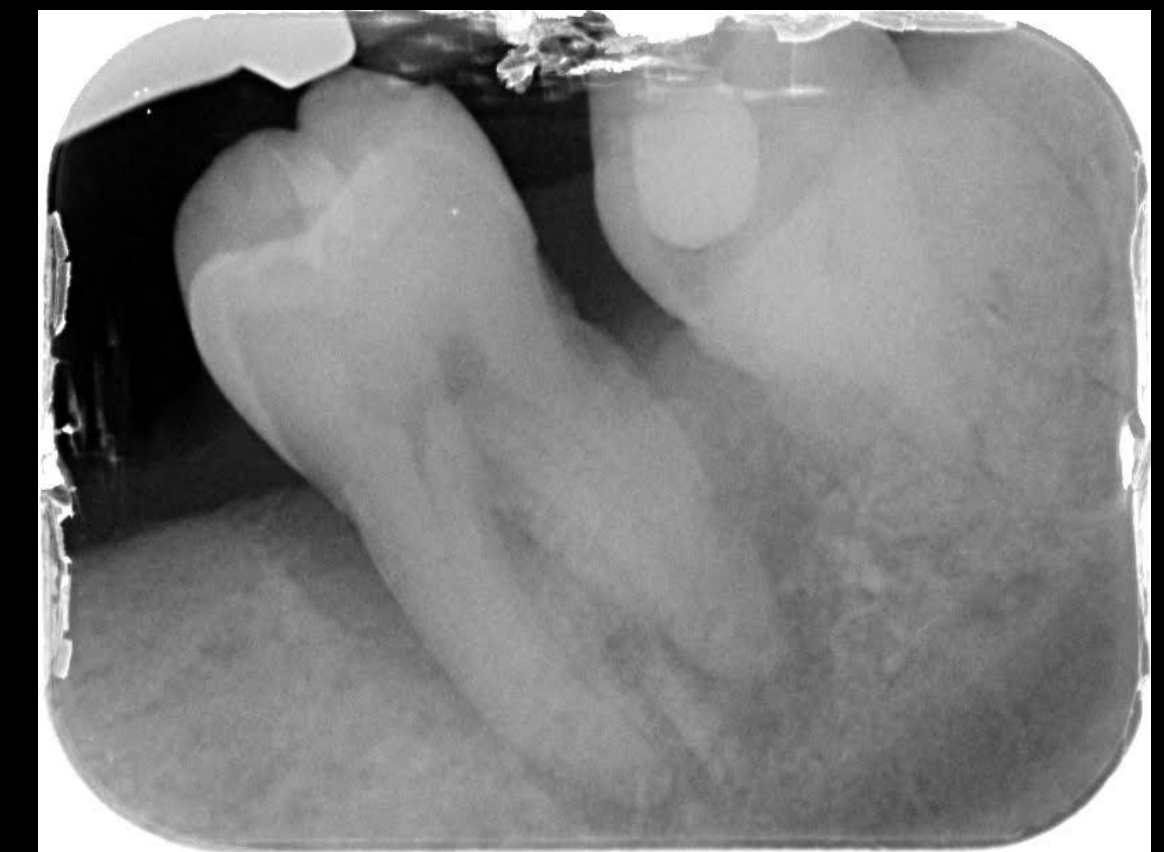
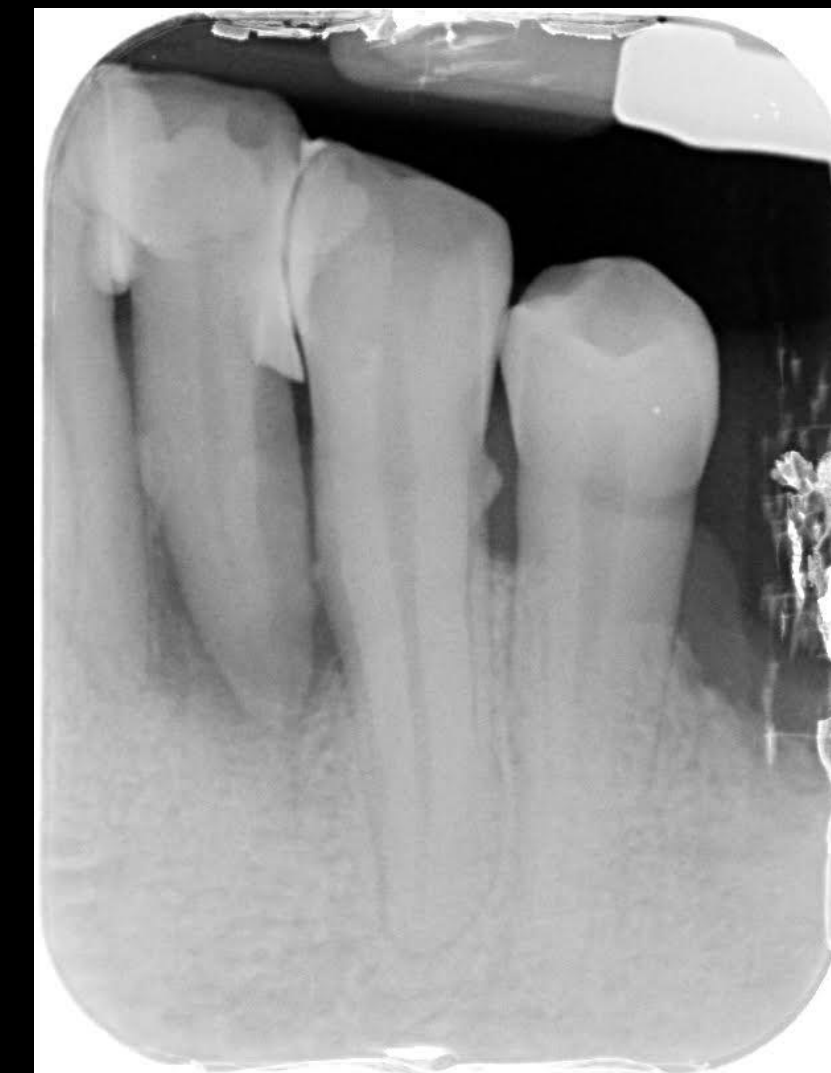
LOWER LEFT QUADRANT

PLEASE PUT CHARTING
HERE



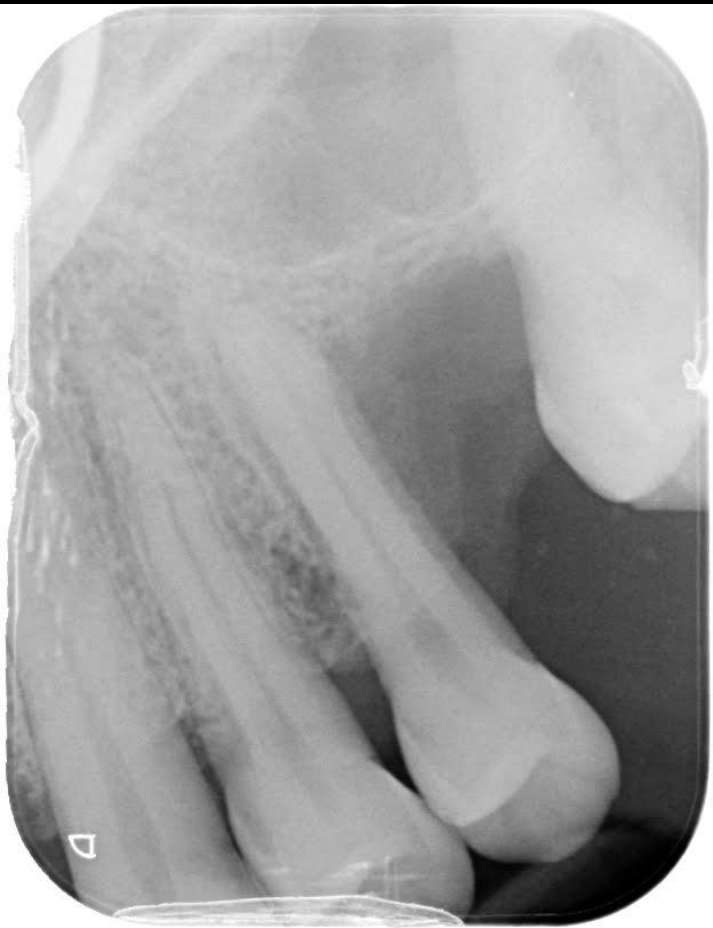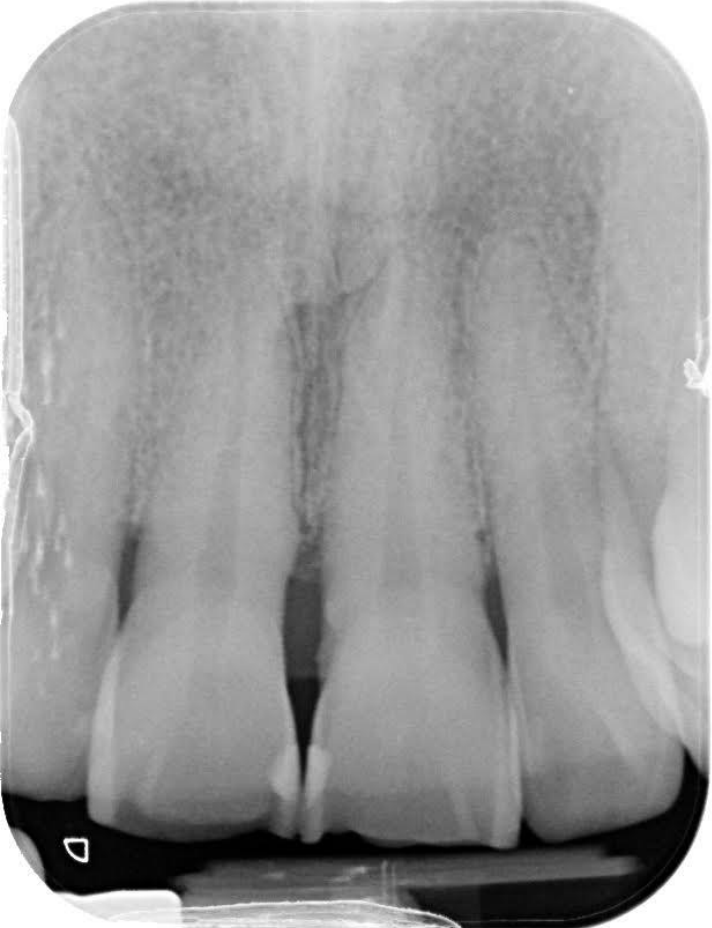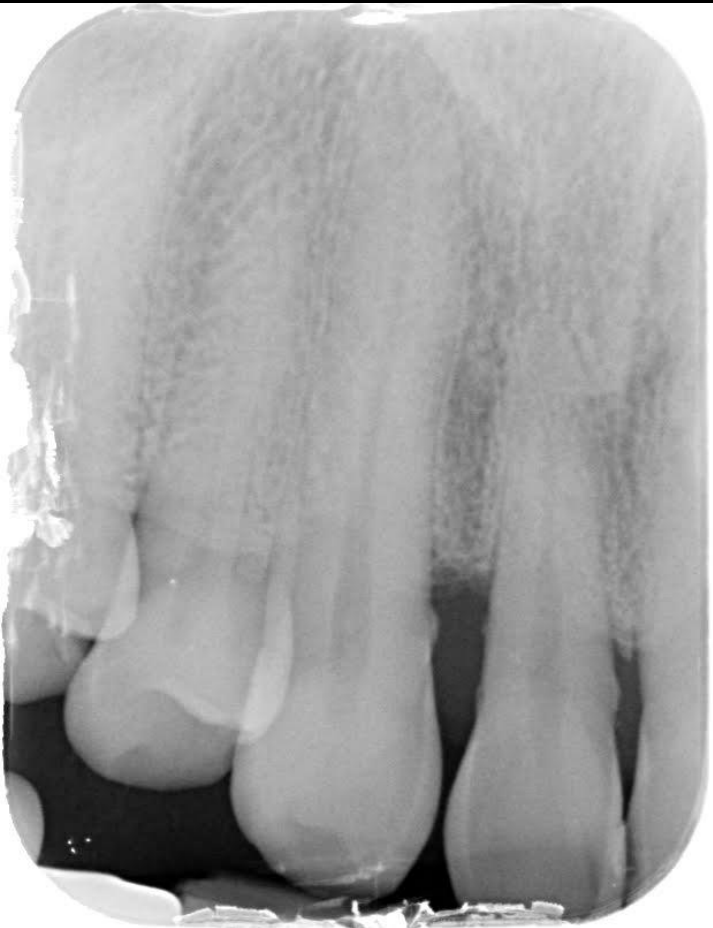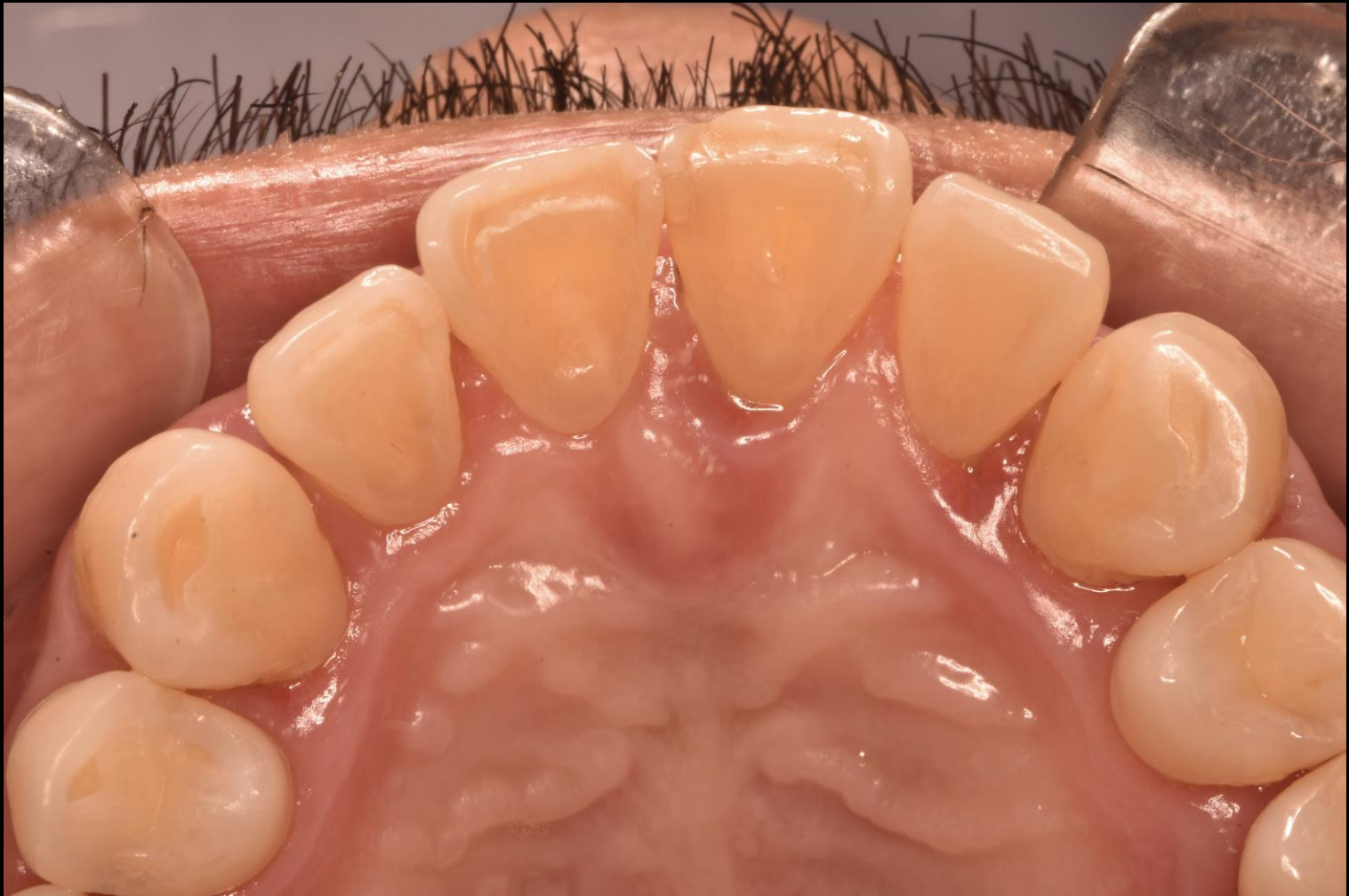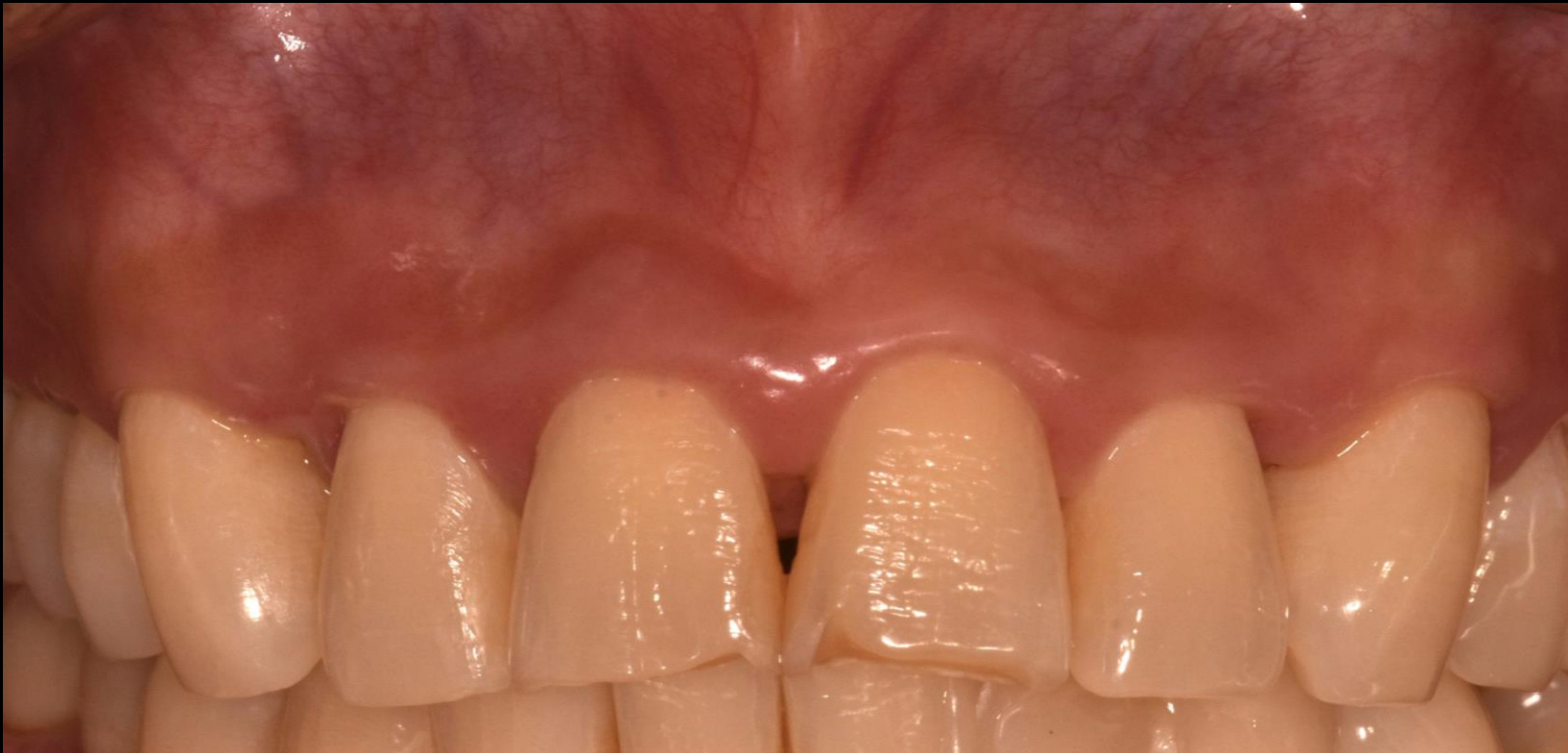DESCRIPTION OF
THE CASE



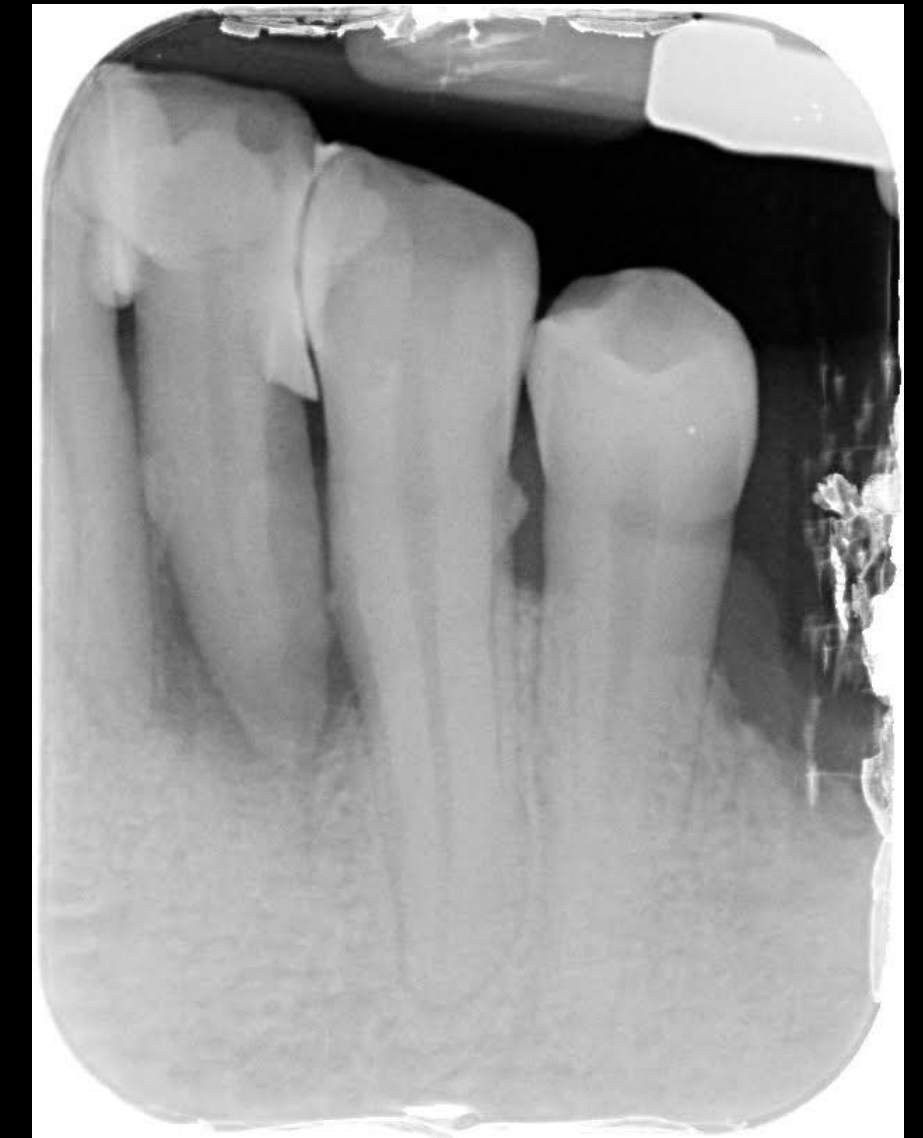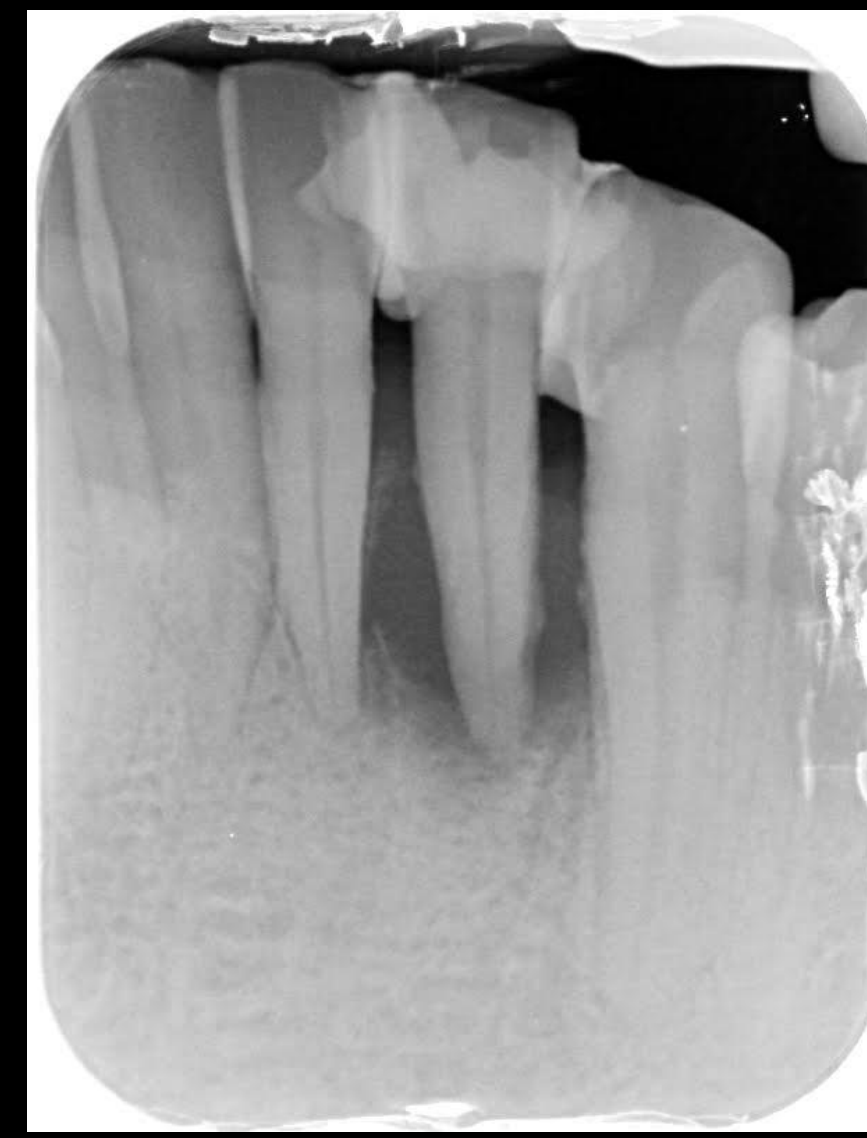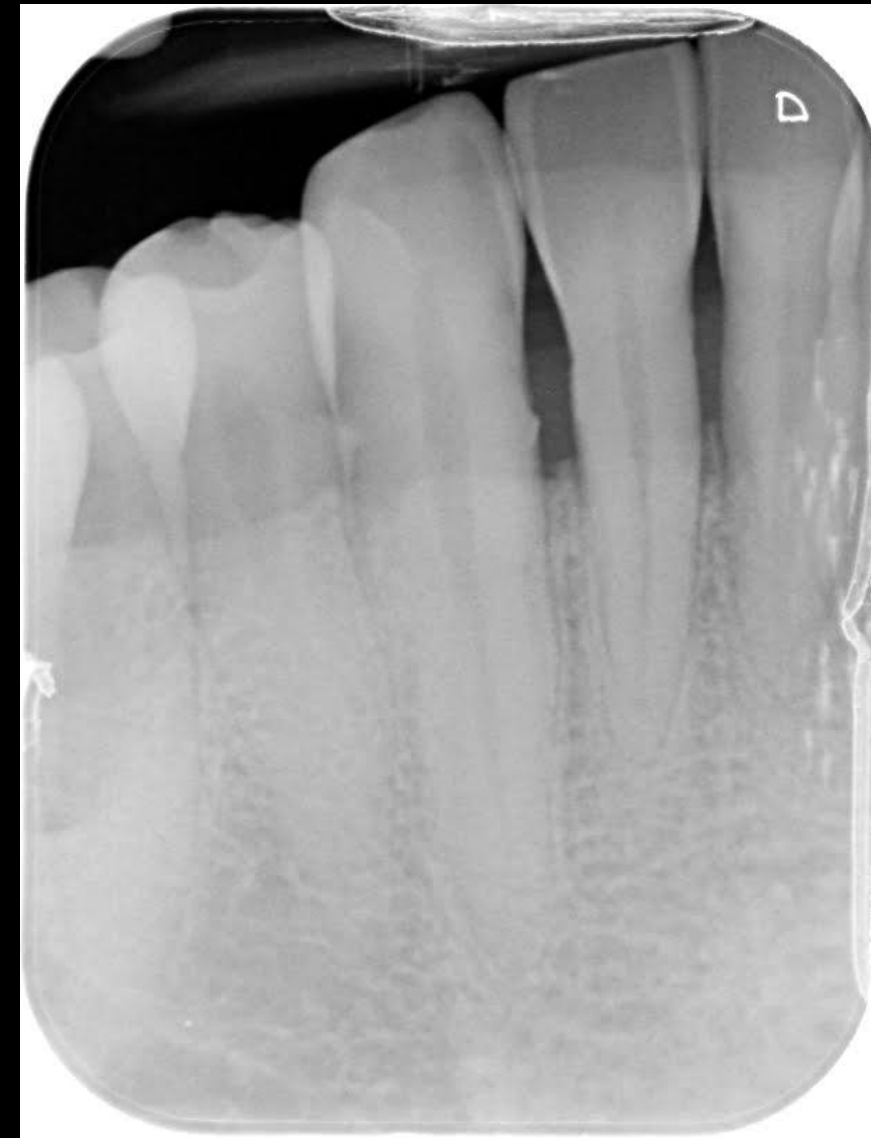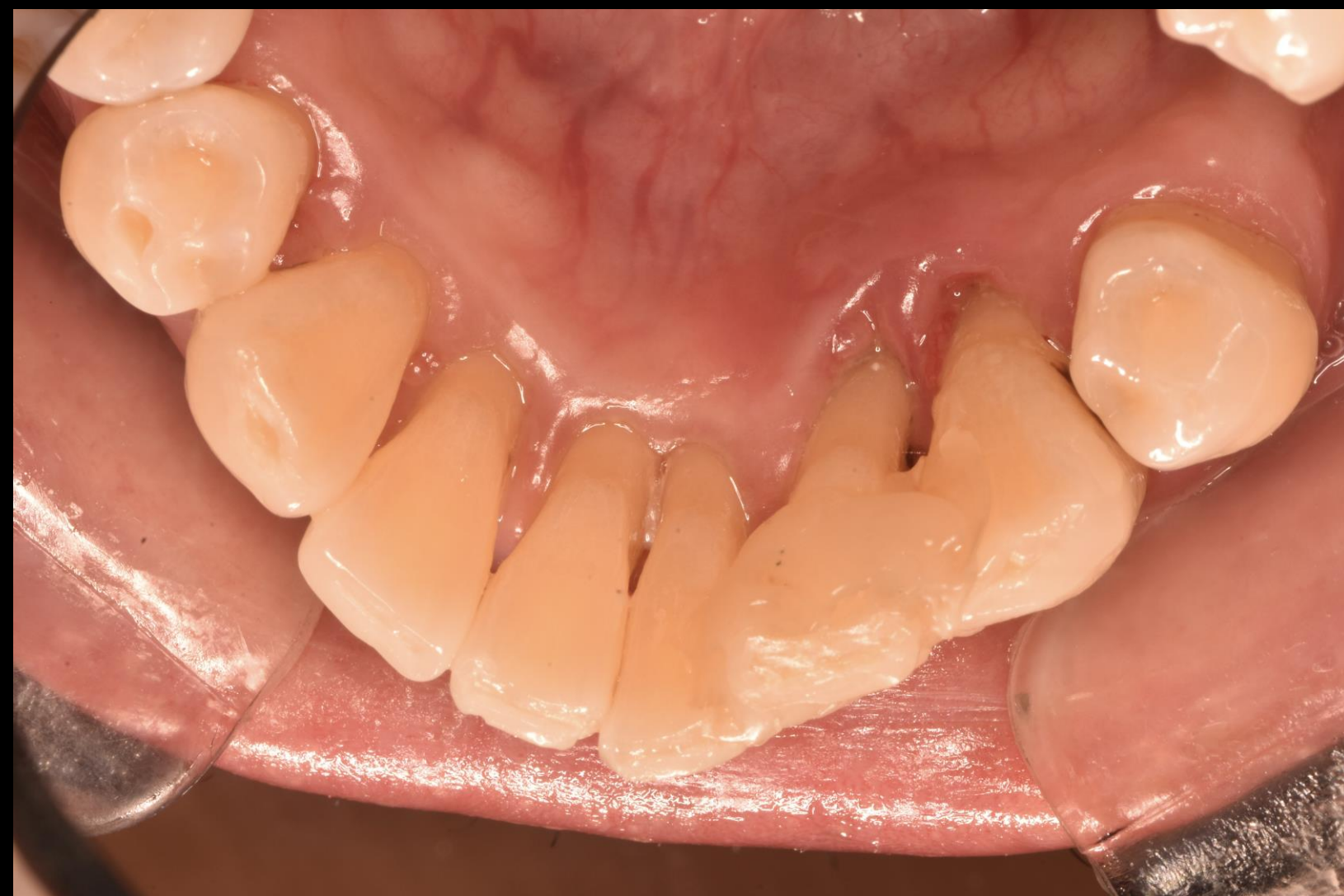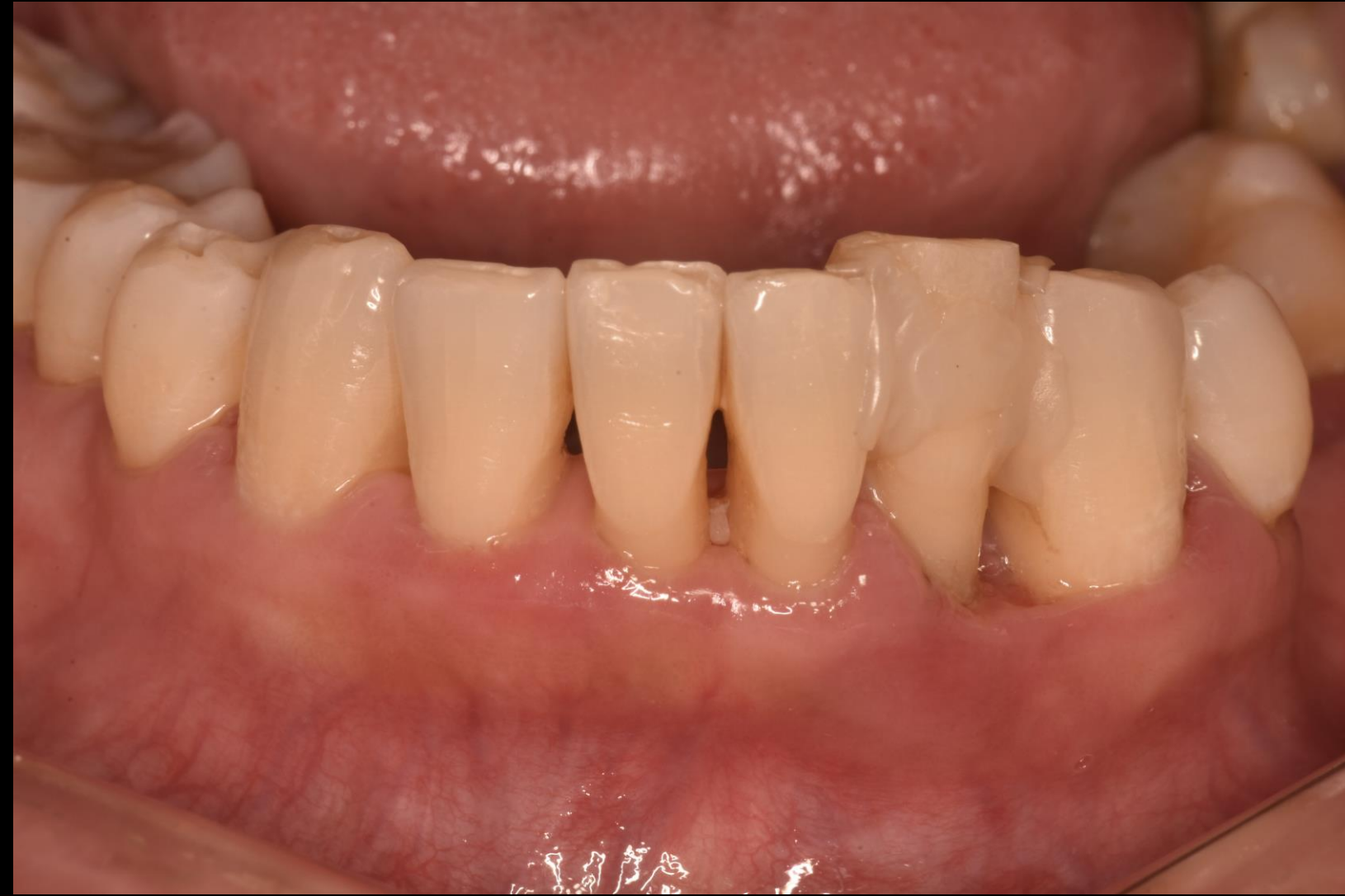MAXILLARY ANTERIORS

PLEASE PUT CHARTING
HERE

DESCRIPTION OF
THE CASE



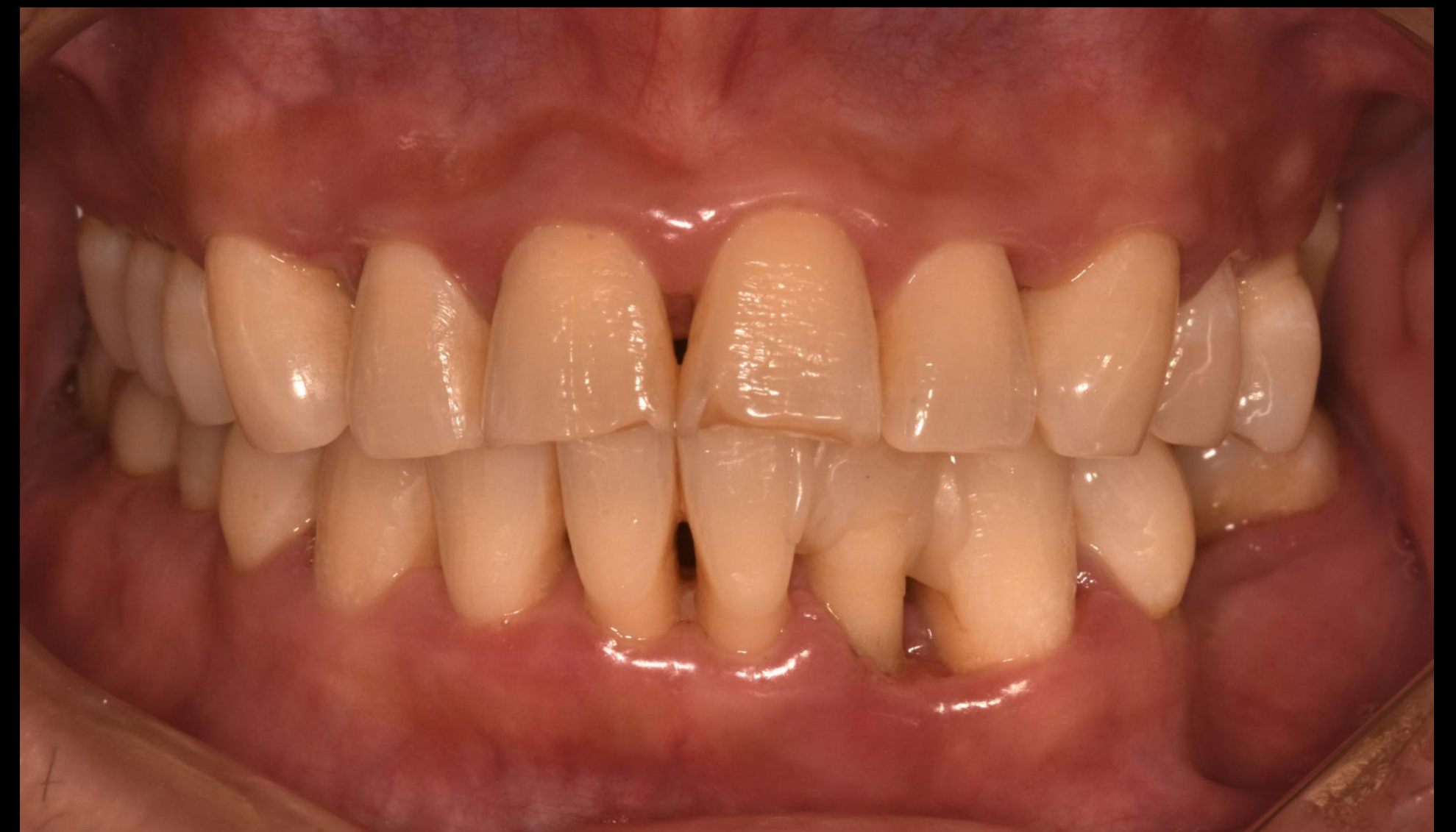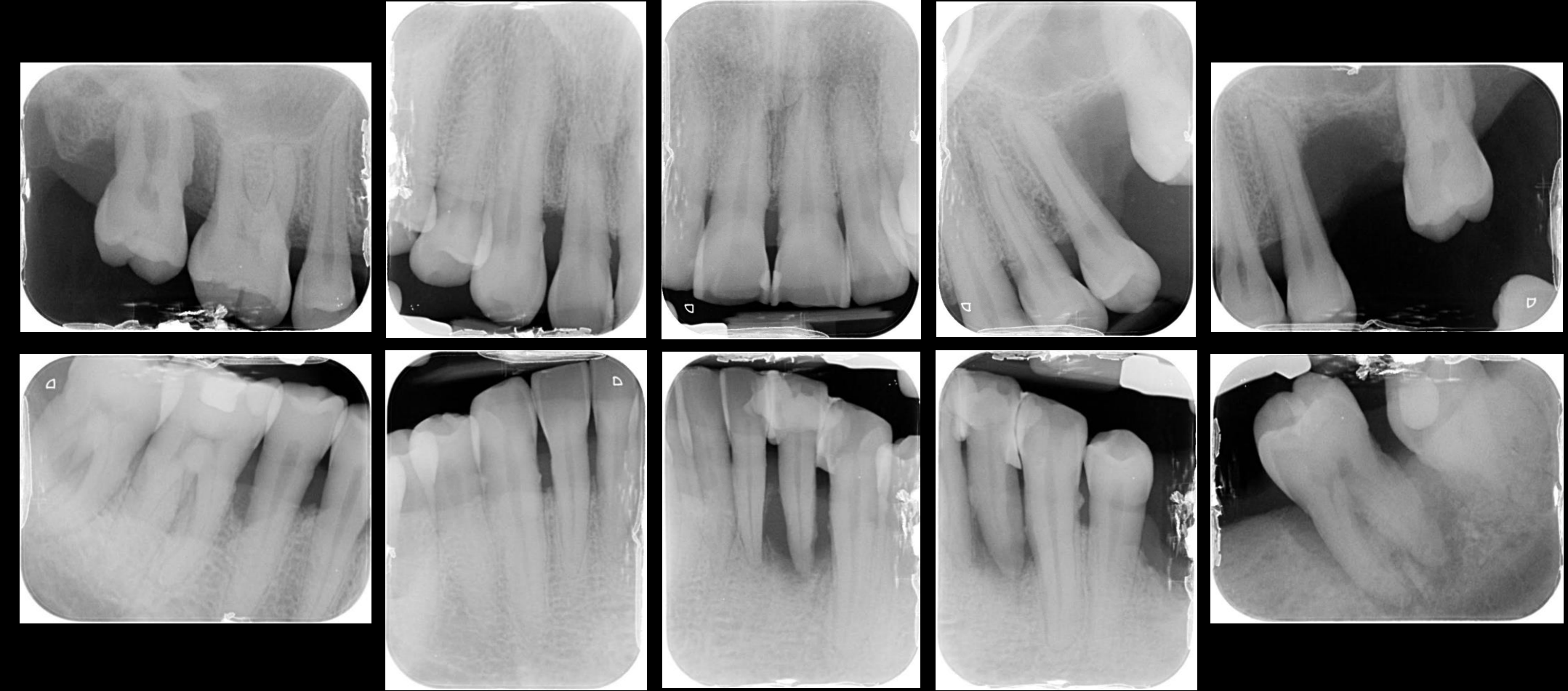
MANDIBULAR ANTERIORS



PLEASE PUT CHARTING
HERE

DESCRIPTION OF
THE CASE

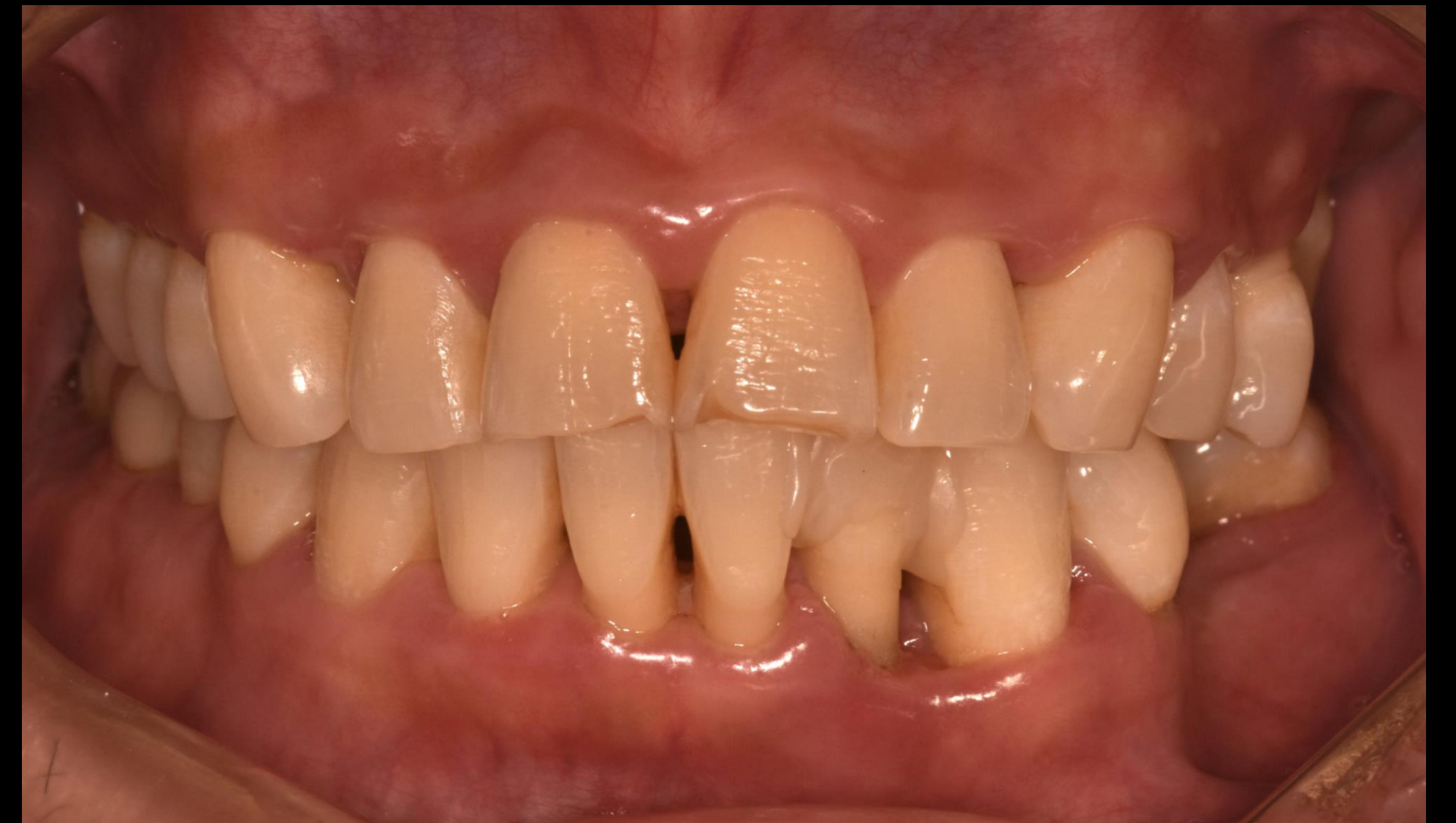DIAGNOSIS:



ETIOLOGY OF PERIODONTAL FINDINGS:

PROGNOSIS, SHORT TERM AND LONG TERM:
INDIVIDUAL TEETH AND OVERALL DENTITION

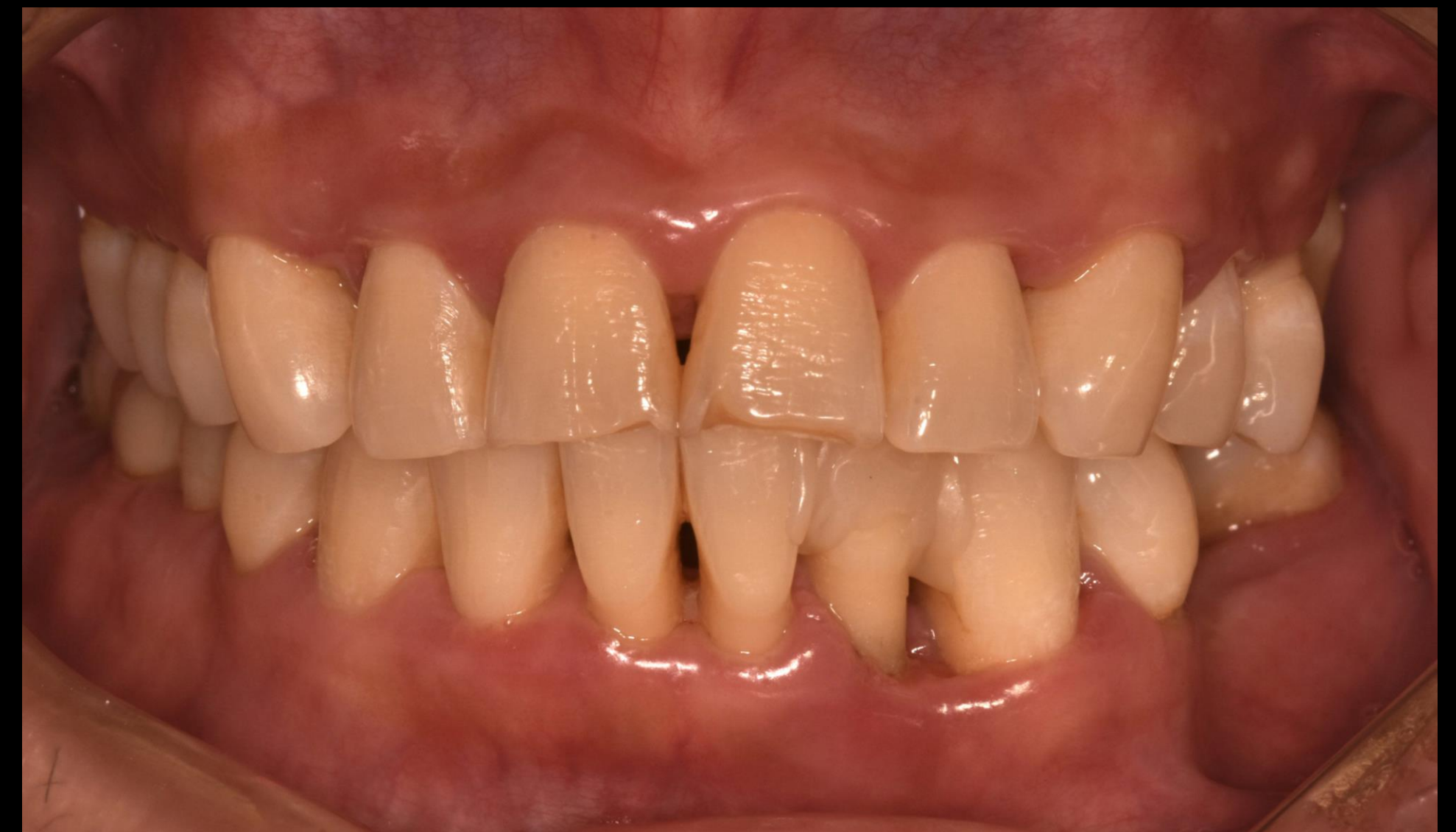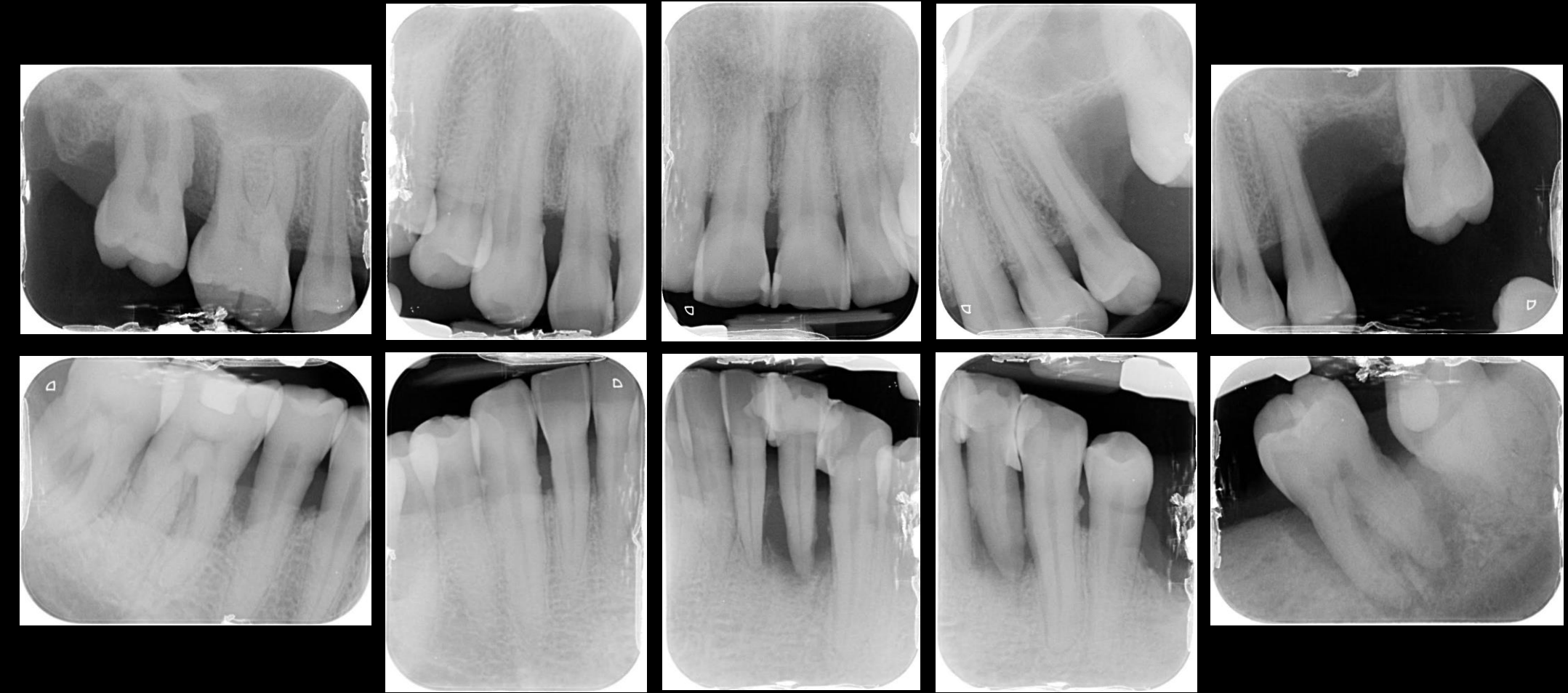
TREATMENT OBJECTIVES:



TREATMENT PLAN:

PLEASE BE SPECIFIC

INCLUDE PROSTHETIC/RESTORATIVE
AND INTERDISCIPLINARY PLANS



ALTERNATIVE TREATMENT PLAN(S):

SURGICAL TREATMENT PROCEDURES:

1. Flap design
2. Flap elevation
3. Bony architecture before and after surgical management
4. Flaps sutured
5. Post-operative images taken after one week and at six weeks or more post-operatively. Additionally, photographs after one year must be included showing all quadrants.

ACTUAL TREATMENT PROCEDURES:

BEFORE

AFTER

EVALUATION OF RESULTS:

MAINTENANCE PROGRAM